Cancer Genetics 243 (2020) 19–47

Contents lists available at ScienceDirect

Cancer Genetics

journal homepage: www.elsevier.com/locate/cancergen

Review Article

Copy number assessment in the genomic analysis of CNS neoplasia: An evidence-based review from the cancer genomics consortium (CGC) working group on primary CNS tumors

Stewart G. Neill[a], Jennifer Hauenstein[a], Marilyn M. Li[b], Yajuan J Liu[c], Minjie Luo[b], Debra F. Saxe[a], Azra H. Ligon[d,*]

[a] Department of Pathology and Laboratory Medicine, Emory University School of Medicine, Atlanta, GA, United States
[b] Department of Pathology, Division of Genomic Diagnostics, Children's Hospital of Philadelphia and Perelman School of Medicine, Philadelphia, PA, United States
[c] Department of Pathology, University of Washington School of Medicine, Seattle, WA, United States
[d] Department of Pathology, Center for Advanced Molecular Diagnostics, Brigham & Women's Hospital and Harvard Medical School, Boston, MA, United States

ARTICLE INFO

Article history:
Received 1 October 2019
Revised 12 February 2020
Accepted 19 February 2020

ABSTRACT

The period from the 1990s to the 2010s has witnessed a burgeoning sea change in the practice of surgical neuropathology due to the incorporation of genomic data into the assessment of a range of central nervous system (CNS) neoplasms. This change has since matured into the adoption of genomic information into the definition of several World Health Organization (WHO)-established diagnostic entities. The data needed to accomplish the modern diagnosis of CNS neoplasia includes DNA copy number aberrations that may be assessed through a variety of mechanisms. Through a review of the relevant literature and professional practice guidelines, here we provide a condensed and scored overview of the most critical DNA copy number aberrations to assess for a selection of primary CNS neoplasms.

© 2020 Elsevier Inc. All rights reserved.

Introduction

Primary central nervous system (CNS) tumors are a heterogeneous group of neoplasms comprising more than 100 histologically distinct types. They can arise in both adults and children from a variety of cell types, including glial cells, neurons and those derived from the meninges [91]. It has become increasingly clear that appropriate clinical management of these tumors relies heavily on an integration of both histologic criteria and genomic data. Indeed, the 2016 WHO Classification of Tumors of the Central Nervous System incorporated genomic data into diagnostic algorithms [64]. Identification of acquired copy number aberrations (CNA) provides information about critical diagnostic, prognostic, and therapeutic biomarkers ([104] and [97,105]). The correlation of CNA and gene mutation profiles with histological features permits more accurate diagnoses and prognoses and supports the creation of personalized treatment plans.

There are striking differences between pediatric and adult brain tumors, including disease incidence, most common tumor types and location, genomic alterations, treatment strategies, and prognosis. The incidence of CNS tumors in children and adolescents ≤19 years old is 5.9 per 100,000 versus 29.9 per 100,000 in adults [20]. Pediatric brain tumors are more likely to be located in the infratentorial parts of the brain (often affecting movement and coordination), while adult brain tumors are more likely to develop in the supratentorial areas of the brain (affecting memory, language, and thought). Embryonal tumors, especially medulloblastomas, and low-grade gliomas are the most common brain tumors in children, while the most common adult brain tumors are meningioma and glioblastoma (GBM). It is not surprising, then, that the genomic profiles of childhood brain tumors may not always align with the adult tumor subgroupings and often represent biologically distinct neoplasms [64]. For example, pediatric diffuse gliomas may display an *H3F3A* K27M mutation distinct from many histologically similar adult counterparts. This genomic difference and the tumor's midline location warrant the establishment of a new entry specifically for this typically pediatric brain tumor - diffuse midline glioma, H3 K27M-mutant – and provide a justification for tar-

* Corresponding author at: Brigham & Women's Hospital, 75 Francis St, Department of Pathology, Center for Advanced Molecular Diagnostics, Shapiro 5048, Boston MA 02115, United States.

https://doi.org/10.1016/j.cancergen.2020.02.004
2210-7762/© 2020 Elsevier Inc. All rights reserved.

geted therapy. Prognostically, pediatric patients often carry better prognoses than do their adult counterparts. More than 75% of children diagnosed at 18 months or younger survive at least five years, with over two-thirds of them having more durable remissions. In contrast, the five-year survival rate for adult CNS tumors is approximately 35% ([2], [81]). Finally, treatment for childhood brain tumors usually differs from treatment for adult tumors. Recent studies have shown good long-term pediatric outcomes with only surgery and therapy with targeted agents. This can help avoid or reduce doses of radiation therapy in these young patients to minimize long-term cognitive, endocrinological, and psychological damage [11].

Since the 1990s, genomic CNA have been detected using conventional cytogenetic analysis (i.e., karyotyping) and fluorescence *in situ* hybridization (FISH). However, the clinical utility of these technologies has been limited by their relatively low resolution, the requirement for karyotype analysis of viable and dividing cells, and the fact that FISH provides only a targeted interrogation of the genome. In contrast, chromosomal microarray analysis (CMA) is a high-resolution and sensitive approach to genome-wide evaluation of copy number and can be deployed with either fresh or formalin fixed-paraffin embedded (FFPE) tissues. Given the importance of identifying acquired CNA in the clinical management of patients with primary brain tumors, many diagnostic genetic laboratories in the United States have adopted CMA as a first-tier test [104]. In this article, we summarize the current knowledge of common CNA associated with primary CNS tumors and their clinical impact on diagnosis, prognosis, and therapeutic management. We also propose best practices for the analysis, interpretation and reporting of CNAs detected in the analysis of CNS tumors, using the most common of these entities as examples.

Background

The acquisition of genomic data has been gaining importance in terms of understanding, diagnosing, and treating central nervous system (CNS) neoplasia, particularly over the last decade. Most recently, this impact has been codified in the 2016 update to the 7th edition of the World Health Organization (WHO) guidelines for the diagnosis of CNS neoplasia [64]. In this update, the WHO included genomic data as part of the definition of several diagnostic entities and highlights the necessity of ascertaining genomic information to make select diagnoses. In contrast, the WHO did not stipulate exactly how practitioners should assess for these diagnostically relevant hallmark genomic changes. This is likely a reflection of the wide variety of institutions, resource settings, platforms, and approaches involved in the current environment surrounding diagnosis and genomic testing of CNS neoplasms. The 2016 WHO update underscores the broad agreement within neuro-oncology that genomic testing is a critical component of the diagnosis of certain CNS neoplasms, but also recognizes variability in test selection, implementation, and availability across institutions.

This document is composed with a similar recognition in mind: the assessment of CNS neoplasia is moving towards incorporation of genomic data as part of diagnostic criteria, but the exact implementation of that transition will vary based on institution. Hence, this document does not prescribe the use of specific testing platforms or modalities. Rather, the focus is primarily on the use of CMA to assess CNA in the diagnosis of CNS neoplasia, while recognizing that other mechanisms of obtaining genome-wide DNA copy number information are also available. With all DNA copy number detection methods, practitioners should be careful to select a platform capable of reliably detecting the range of abnormalities important to the diagnosis of CNS neoplasms. CMA will not detect any balanced rearrangements, therefore tumors driven by this mechanism are not suitable targets for this analytical approach. Furthermore, the focus on evaluation of DNA copy number data does not preclude recognition of other critical genomic changes of known diagnostic relevance, such as: single nucleotide variations (SNVs), epigenetics, changes in expression or methylation and, as mentioned above, balanced rearrangement. As such, clinically relevant mutations, fusions and other genomic phenomena will also be referenced as necessary to provide context for the use of copy number data.

Below we review the types of data that are attainable through CMA of the most common CNS neoplasms. We include descriptions of both adult and pediatric tumors, as those tumors common in pediatric patients (for these purposes, patients less than 20 years of age at diagnosis) are often genetically distinct from even similarly-named tumors found in adult patients. Given the breadth and complexity of primary CNS tumors, our discussion is focused on the abnormalities most critical for diagnostic, prognostic, or therapeutic purposes. Considering the inclusion of many of these abnormalities in published documents outlining and guiding diagnostic practice, such as the 2016 WHO update, the 2019 NCCN guidelines, and the 2019 International Collaboration on Cancer Reporting (ICCR) data set [66], in this space we did not opt to propose additional recommendations regarding the use of this data. Rather, we provide annotations stipulating the typical use of these abnormalities in a manner similar to that described in the ICCR data set. These annotations are present in the accompanying Tables, separated into adult and pediatric-predominant tumor types with some entities overlapping. Abnormalities that constitute a requirement of or form a portion of the diagnosis of a WHO-defined tumor have been designated with a (W). Abnormalities that are treated or referenced as a part of characterizing a current diagnostic entity, but are not formally required by the WHO, are designated with a (D). Abnormalities that are treated or referenced as supportive of a diagnosis, but perhaps not critical, are designated with an (S). In this manner, we aim to provide a guide for a variety of practitioners in considering which abnormalities are of critical importance in testing different tumor types [64,66,75]. Many additional aberrations are also listed in the accompanying Tables.

Pre-analytic, analytic, and post-analytic variables

Platform selection

Many different CMA platforms are in clinical use, including array-based comparative genomic hybridization (aCGH) and a variety of single nucleotide polymorphism (SNP) arrays. The advantages of many aCGH platforms include longer probe lengths (60 to 65-mers), relatively high signal to noise ratios, and the option to customize probe coverage over selected areas of the genome; of note, some aCGH platforms are also designed for SNP detection. In contrast, most SNP probes are shorter (25-mers) but enable inferences to be made about zygosity, ploidy, and loss of heterozygosity (LOH), features that may also be important to assess. In some cases, detection of targeted mutations can also be achieved using SNP probes [42,86]. Platforms that utilize CGH plus SNP probes, or SNP plus copy number probes, have been used clinically in recent years [116]. The selection of a given platform must take into account several factors, including: (1) required DNA inputs, particularly to accommodate small biopsies or resections, (2) the utility of identifying LOH events, (3) the value of identifying ploidy changes, and (4) whether a platform can be used with either fresh tissue or formalin-fixed, paraffin-embedded (FFPE) tissue as a starting

material. In addition, targeted next generation sequencing (NGS) analysis is being used in some settings for concurrent detection of sequence variants and CNA. However, it is also critical to understand the limitations of NGS-based CNA analysis, which in most cases should be comparable to the requirements for array platforms [70,71]. Certainly while known gene fusions, such as the *KIAA1549-BRAF* fusion in pilocytic astrocytoma, can be identified either using CNA or through NGS, targeted fusion assays provide another mechanism by which this information may be obtained [128]. Finally, a very few academic centers have implemented clinical use of methylation array technologies based on burgeoning efforts detailing methylation array profiling in brain tumor diagnostics. In the coming years this technology may be more widely adopted for clinical use. Of note, while copy number profiles can also be derived from methylation array data, the lack of SNP detection complicates assessments of ploidy and precludes assessment of LOH [18,19,46].

Tumor burden, genomic heterogeneity, and specimen selection

The minimum tumor burden with which specific aberrations can be identified is fairly consistent across platforms (generally 10-15%; [52]). It is important to obtain a specimen with as high a tumor content as possible, particularly as the ability to identify subclonal aberrations is proportional to the frequency with which they occur in the tumor. If testing is being performed to compare CMA results of a primary resection versus a recurrent tumor, the ability to identify either residual clones or new clones that have the potential to impact treatment will rely on the degree to which they are represented in the tumor. Particularly for these reasons, neuropathologists play a critical role in specimen review and tissue selection. By determining whether FFPE cores or scrolls should be submitted for analysis and whether materials must undergo microdissection prior to DNA isolation, neuropathologists can enrich a given specimen for tumor tissue rather than normal parenchyma, and in doing so they increase the likelihood that the appropriate tissue is evaluated. At many institutions diagnostic geneticists work closely with neuropathology colleagues to interpret and integrate genomic data into a surgical pathology report that draws together all relevant diagnostic data in a single document. Lastly, it should be stated that an important advantage to working with FFPE tissues is that histologic review can guide selection of the most important areas of a specimen. This, in turn, increases the likelihood that CMA results are derived from neoplastic cells rather than adjacent normal tissue. Normal tissue components can effectively quench identification of low-level gains and losses; for example, when known targets of genomic amplification appear to be focally gained in a single copy, this could indicate a true amplification in a sub-clonal population or it could indicate excess normal tissue was present and quenched even the highest level CNA. The risk of the latter scenario, of course, is that lower level CNA can go undetected.

CNA analysis

Laboratories must establish parameters to be used for reporting aberrations, which can be size-based or target tumor-specific regions or genes, or both. In addition, each laboratory must establish thresholds for calling clonal aberrations and have standard operating procedures (SOP) in place for how clinically relevant CNAs will be reported if the log2 ratios fall below the established thresholds; one scenario in which this can occur is when tumor content is relatively low, or when a given aberration is present only in a minor sub-clonal population. In this case, a recommendation may be included to confirm CMA findings using orthogonal methods. Another example is that of tumor ploidy, which can be detected using SNP CMA but is challenging, if not impossible, to appreciate using CGH platforms.

Copy neutral loss of heterozygosity (CN-LOH)

CN-LOH may be detected using SNP CMA but not by aCGH. When intervals of CN-LOH are identified that overlap with known tumor suppressor genes, such as *PTEN* or *TP53*, it should be considered that the remaining allele may be mutated [80]. Consequently, reporting CN-LOH may be a useful practice despite the fact that identification of any particular CN-LOH event is unlikely to be diagnostic for any tumor type. Regardless, laboratories should establish criteria for reporting CN-LOH. For example, laboratories should determine whether CN-LOH is only reported when it exceeds a pre-determined size, when it overlaps with known tumor suppressor genes, or when any other specific criteria have been met.

Chromothripsis

Chromothripsis was first described as a form of genomic instability that includes up to hundreds of clustered rearrangements affecting one or a few chromosomes [68,115]. Given sufficient resolution, chromothripsis can be observed using most CMA platforms, on which it manifests as a series of copy number gains, losses or neutral segments over a defined chromosomal segment or a whole chromosome; the currently accepted definition of chromothripsis is a “copy-number profile that has alternating copy states in a single region—typically a single chromosome or chromosome arm—that contains at least ten distinct alternating copy-number segments” [72]. The phenomenon is thought to involve multiple double-stranded DNA breaks that occur during a shattering of the chromosome, or chromosomal region, followed by fusion of DNA segments as the genome attempts self-repair. While it is not specific to any particular tumor type, among primary CNS tumors chromothripsis has been observed as a recurrent finding in medulloblastoma, for which it has been associated with an increased frequency of *TP53* mutations [77,99]. In ependymomas, chromothripsis has been associated with *RELA* fusions at 11q13.1 [87]. Interestingly, in some gliomas, an association between chromothriptic events and *IDH* mutation status also has been described [26,99].

Mutation analysis

While the focus of this document is the classification of recurrent CNAs in the most common primary CNS tumors, a diagnostic genetic testing complement would be incomplete without concurrent evaluation of targeted mutations in these same specimens. In some instances, identification of specific mutations or fusion genes, such as those in *IDH1/IDH2*, define specific groups of CNS tumors. In others, identification of specific mutations (e.g., *CTNNB1* mutations in a WNT-activated medulloblastoma) can help assign unusual tumors to a molecular class when specific CNAs are not detected [64]. Tumorigenesis may be driven by genomic events other than CNA. Therefore, we include Tables 1 and 2 to summarize the most common gene mutations associated with specific primary CNS tumors. Integration of mutation data with CNA and histologic findings can further classify specific tumor types.

Table 1
Genomic aberrations in pediatric primary CNS tumors.

PEDIATRIC TUMORS	SUBTYPES	BROAD ABERRATIONS (> 10Mb)	FOCAL ABERRATIONS (< 10 Mb)	CLINICAL FEATURES	REFERENCES (PMID/PMCID)
GLIOMAS					
Low grade glioma, WHO grade I	Pilocytic astrocytoma/pilomyxoid astrocytoma	Duplication of 7q34 {D}; Some tumors show polysomy 7 {S}; Other polysomies more common in adult PA {S}	Fusions: KIAA1549-BRAF fusion (via 3′BRAF duplication) {D}, other BRAF partners reported; NTRK fusions (rare); FGFR1 fusions (rare) {all S} Mutations: BRAF V600E (particularly extra-cerebellar tumors) {D}; FGFR1 (midline PA) {S}; NF1 (germline) {S}, other MAPK pathway mutations Loss: NF1 in optic pathway PA {germline S}	Classic PA are cerebellar (most commonly associated with BRAF duplication); PA in patients with germline NF1 alterations often develop as optic gliomas; Surgical resection can be curative; PMA generally more aggressive than PA; BRAF fusions and BRAF mutations generally are mutually exclusive	WHO CNS Tumors (2016) 19016743; 2761618; 18716556; 25461780 25664944; 26378811; 3429698; 23817572; 23583981; 18974108; 23278243; 21274720; 29466156 https://www.fda.gov/Drugs/InformationOnDrugs/ApprovedDrugs/ucm626720.htm.
	Angiocentric glioma	Aberrations involving 6q24-q25	Fusions: MYB-QKI rearrangement/deletion (classic histology) {S} Rearrangement: MYB alone (atypical histology) Amplification: MYB (atypical histology)	Generally indolent tumors; surgical resection can be curative	26829751; 23633565; 26778052; 23583981

(*continued on next page*)

Table 1 (*continued*)

PEDIATRIC TUMORS	SUBTYPES	BROAD ABERRATIONS (> 10Mb)	FOCAL ABERRATIONS (< 10 Mb)	CLINICAL FEATURES	REFERENCES (PMID/PMCID)
	Ganglioglioma	Only 30% are abnormal by karyotype Gain: polysomy 7	Mutations: BRAF V600E {D} in 20-60% of cases (can be concurrent with CDKN2A homozygous deletion) Fusions: KIAA1549-BRAF (rare)	Generally indolent tumors for which surgical resection can be curative	25461780; 23583981; 11996800; 23609006; 29880043
	Dysembryoplastic neuroepithelial tumor (DNET)	No specific changes	Mutation: intragenic duplication or mutation of FGFR1; BRAF V600E	Benign with excellent prognosis even with subtotal resection	26920151; 23442159; 21937911
	Rosette forming glioneuronal tumor	Gain: 1q, 7, 9, 16 Loss: 1p Amplification: 9q34.2, 19p13.3	Mutation: PIK3CA, FGFR1 {S} Mutation: PIK3CA, FGFR1 {S}	Generally indolent tumors; surgical resection can be curative	27893178; 26371886
Low grade glioma, WHO grade II	Diffuse astrocytoma	No diagnostic aberrations; Gain: (8q13.1/MYBL1 tandem duplication)	Rearrangement: MYBL1 truncating rearrangements and tandem duplication {S}, Amplification/rearrangements: MYB {S}, FGFR1 rearrangements (duplication TKD) {S} Mutation: BRAF {S}, FGFR1 {S}, IDH {W - pediatric-type diffuse astrocytoma is IDH wt}	Anaplastic features associated with decreased progression free survival	25664944; 23633565; 26061751; 26824661; 26004297; 25461780; 23583981
	Pleomorphic xanthoastrocytoma (PXA)	Polysomy 3, polysomy 7 observed {S} Loss: monosomy 9 / 9p deletion or cnLOH(9p) {S}	Mutations: BRAF V600E in ~60% {D}; TP53 (6%) Loss: CDKN2A/CDKN2B {S}		25461780; 23583981; 16909113; 12484572

(*continued on next page*)

Table 1 (*continued*)

PEDIATRIC TUMORS	SUBTYPES	BROAD ABERRATIONS (> 10Mb)	FOCAL ABERRATIONS (< 10 Mb)	CLINICAL FEATURES	REFERENCES (PMID/PMCID)
Anaplastic astrocytoma, WHO grade III	IDH-mutant or IDH-wild type, may represent a variety of genomic entities	Gain: 1q, 7/7q, 8q, 10p Loss: 6q, 9p, 10q, 11/11p, 12q, 13q, 14q, 17p, 19q, 22/22q	Mutation: IDH1/2 (rare in pediatric AA), ATRX, TP53	IDH-wild type astrocytomas can be more clinically aggressive than those that are IDH-mutant	1891902; 26004297; 25461780; 24140581; 5323185; 27230974; 27196377; 26061751; 25962792; 29687258 1891902; 26004297; 25461780; 24140581; 5323185; 27230974; 27196377; 26061751; 25962792; 29687258
Other	Anaplastic PXA, WHO grade III / Ganglioglioma, WHO Grade III	Loss: monosomy 9 / 9p deletion, but no diagnostic findings	Mutation: BRAF V600E less common here than in PXA, grade II; TERT promoter Loss: biallelic CDKN2A/CDKN2B Amplification: TERT	CDKN2A/CDKN2B loss may correlate with anaplastic histology	WHO CNS Tumors (2016) 25318587; 23096133; 21274720; 30051528; 28181325; 30240866
Glioblastoma, WHO grade IV	IDH-mutant or IDH-wild type, may represent a variety of genomic entities	Gain: 1q, 2q, 3q, 7, 16p, 17q, 21q Loss: 6q, 8q, 9p, 9q, 10q, 13q, 17p, 22q Chromothripsis: observed	Loss: PTEN, RB1, TP53, CDKN2A/B/C Fusions: FGFR-TACC; NTRK (infantile GBM) Amplification: PDGFRA, MYCN, MET, CDK4, CDK6 (rarely EGFR, MDM2) Mutation: IDH1/2 (rare in pediatric GBM), KRAS, RAS pathway, RB1 pathway, TP53 pathway, FGFR1, H3.3/H3.1-K27M (predominantly in diffuse midline tumors), H3.3 G34R/V (hemispheric tumors), PDGFRA, NF1, SETD2, ATRX, DAXX	Overal poor prognosis	25752754; 25727226; 26328271; 22837387; 25754088; 25461780; 1891902; 23417712; 5323185; 29687258; 20479398; 24959384; 29466156; https://www.fda.gov/Drugs/InformationOnDrugs/ApprovedDrugs/ucm626720.htm.

(*continued on next page*)

Table 1 (*continued*)

PEDIATRIC TUMORS	SUBTYPES	BROAD ABERRATIONS (> 10Mb)	FOCAL ABERRATIONS (< 10 Mb)	CLINICAL FEATURES	REFERENCES (PMID/PMCID)
Diffuse midline glioma, H3 K27M mutant		Gain: 1q, 2 {S} Loss: 10q Chromothripsis: 2p	Three molecular subgroups: MYCN subgroup: no mutations; chromothripsis leading to amplification of MYCN and ID2; Silent subgroup: no recurrent copy # changes, few mutations; H3-K27M subgroup: MYC, PDGFRA gain/amplification; RB1, TP53 deletions Mutation: ACVR1{S}, H3F3A {W}, HIST1H3B/C {W}, TP53 {S} Loss: CDKN2A, PTEN, RB1, TP53 {S} Amplification: MYC, MYCN, ID2, PDGFRA,CDK4/6, CCND1-3, MET {S} Fusion: NTRK	Overall poor prognosis regardless of subgroup	3280796; 24705254; 24705252; 27048880; 26175967; 24705251; 28966033; 29466156; https://www.fda.gov/Drugs/InformationOnDrugs/ApprovedDrugs/ucm626720.htm.
EPENDYMOMA (in order of increasing WHO grade)		DNA-based methylation classifies tumors across anatomical sites (posterior fossa, supratentorial, spinal), grades and age groups	Fusion: RELA fusion, YAP1 fusions (supratentorial tumors) {W}; Mutation: NF2 (spinal tumors) {S}	Intracranial (in children, 90%) or spinal tumors; Histological distinction between WHO grade II and III is of questionable relevance; Prognostic differences among tumors suggested on the basis of methylation analysis	WHO CNS Tumors (2016) 25965575; 21627842; 24939246; 22516549

(*continued on next page*)

Table 1 (*continued*)

PEDIATRIC TUMORS	SUBTYPES	BROAD ABERRATIONS (> 10Mb)	FOCAL ABERRATIONS (< 10 Mb)	CLINICAL FEATURES	REFERENCES (PMID/PMCID)
	Classic ependymoma (no WHO grade assigned)	Gain: 1q, 5, 7, 9, 11, 18, 20 {all S} Loss: 1p, 3, -6/6q, 9p, 13q, 17, 22 {all S}	Loss: CDKN2A/CDKN2B (supratentorial) {S} Mutation: NF2 (spinal tumors) {S}	Usually intracranial, spinal tumors (myxopapillary) are rare; 80% of pediatric tumors develop in posterior fossa (PF); Supratentorial tumors preferentially show monosomy 9; 1q gain is unfavorable prognostic indicator in PF tumors; spinal tumors associated with NF2 (germline); children have worse outcomes than adults	25965575; 22338015; 28371821; 19531565
	Subependymoma, WHO grade I	Typically balanced genomes Loss: -6/6q in spinal tumors {S}	No diagnostic mutations	Favorable prognosis	21959044; 21840481 WHO CNS Tumors (2016) 21959044; 21840481 WHO CNS Tumors (2016)
	Myxopapillary ependymoma, WHO grade I	Aneuploidy: multiple chromosomes gained {S}	Mutation: NF2 (including germline) in spinal tumors	Less common but more aggressive in children	25965575; 3991130; 20425037; 25957288; 25965575; 22516549

(*continued on next page*)

Table 1 (*continued*)

PEDIATRIC TUMORS	SUBTYPES	BROAD ABERRATIONS (> 10Mb)	FOCAL ABERRATIONS (< 10 Mb)	CLINICAL FEATURES	REFERENCES (PMID/PMCID)
	Ependymoma, RELA fusion-positive, WHO grade II or III	Gain: 1q Aneuploidy: multiple chromosome losses and gains Chromothripsis: chromosome 11 (70% of supratentorial tumors) {S}	Fusion: c11orf95-RELA (supratentorial tumors) {W} Loss: CDKN2A/B (may help distinguish from other supratentorial ependymomas)	Unfavorable prognosis; occur in infants or children	25965575; 24553141; 28371821
	Anaplastic ependymoma (no WHO grade assigned)	Epigenetic studies suggest range of abnormalities: balanced or unbalanced genomes	Mutation: NF2 (including germline) in spinal tumors Fusion: RELA fusions, YAP1 fusions can correspond to anaplastic histology	Mostly intracranial tumors, rarely in spinal cord; YAP1 fusion tumors can occur in infants	25965575
EMBRYONAL TUMORS					WHO CNS Tumors (2016)
Medulloblastoma	WNT-activated	Loss: monosomy 6/6q- as sole finding in 85% {D}	Mutation: CTNNB1 {W}, APC (germline mutations in Turcot syndrome) {W}, DDX3X, TP53,SMARCA4, KMT2D	Common in children > 3 years of age (particularly adolescent females); typically show classic histology, rarely metastasize; overall favorable prognosis	22832581; 24493713; 22134537; 24894640; 16258095; 22832581; 24493713; 22358457; 25043047; 22820256; 26976201; 20823417; 22265402; 3889646; 16567768 20940197; 23175120; 28545823

(*continued on next page*)

Table 1 (*continued*)

PEDIATRIC TUMORS	SUBTYPES	BROAD ABERRATIONS (> 10Mb)	FOCAL ABERRATIONS (< 10 Mb)	CLINICAL FEATURES	REFERENCES (PMID/PMCID)
	SHH-activated	Gain: 3q Loss: 9q, 10q, 14q, 17p {all S} Ploidy changes: Tetraploidy associated with chromothripsis and TP53 mutations Chromothripsis: associated with TP53 mutation {S}	Mutation: TP53 {W - in context of SHH medulloblastoma}, PTCH1 {D} Loss: PTCH1, PTEN {D} Amplification: GLI2 (TP53-mutant tumors) {D}, MYCN (TP53-mutant tumors), YAP1 {S}, IGF1R, PPM1D {S}, MIR17/92, MDM4 {S} TP53 wild-type tumors: PTCH1 (germline mutations in Gorlin syndrome) {D}, SMO {D}, SUFU (can be germline) {D}, TERT promoter {S} TP53-mutant tumors: can be germline {S}	Common in infants, rare in children, most common type of medulloblastoma in adults; Desmoplastic (or nodular) histology common; TP53 wild-type usually correlate with extensive nodularity or desmoplastic histology; TP53-mutant tumors correlate with metastatic disease	24651015; 21681522; 22832581; 24493713; 24077351; 22134537; 22832581; 24493713; 22358457; 25043047; 22820256; 26976201; 20823417; 22265402; 3889646 16567768; 20940197; 23175120; 28545823
	Group3	Gain: 1q, 7, 18q Loss: 5q, 8, 10q, 11p, 16q Rearrangement: idic(17)(p11.2) {S} Ploidy changes: tetraploidy in 40-50% of Group3/Group4 tumors	Mutation/Amplification: MYC (mainly in infants) {S}, OTX2, SMARCA4, CTDNEP1, LRP1B, KMT2D Fusions: PVT1-MYC {S}, PVT1-NDRG1, GFI1/GFI1B structural variants	Usually classic histology ~ 50% are metastatic at time of diagnosis Not generally observed in adults	22832581; 25043047; 24493713; 23175120; 22134537; 22832581; 24493713; 22358457; 25043047; 22820256; 26976201; 20823417; 22265402; 3889646; 16567768 20940197; 23175120; 28545823

(*continued on next page*)

Table 1 (*continued*)

PEDIATRIC TUMORS	SUBTYPES	BROAD ABERRATIONS (> 10Mb)	FOCAL ABERRATIONS (< 10 Mb)	CLINICAL FEATURES	REFERENCES (PMID/PMCID)
	Group4	Gain: 7, 18q Loss: X, 8, 11p Rearrangement: idic(17)(p11.2) in >80% {S} Chromothripsis: rare, but associated with TP53 loss when observed	Mutation: KDM6A {S}, KMT2C {S}, TP53 Amplification: MYCN {S}, CDK4, CDK6 {S}, OTX2 Rearrangement: SNCAIP tandem duplication {S}; GFI1/GFI1B structural variants	Rarely seen in infants; usually classic histology	22832581; 25043047; 24493713; 23175120; 22134537; 22832581; 24493713; 22358457; 25043047; 22820256; 26976201; 20823417; 22265402; 3889646; 16567768 20940197; 23175120; 28545823
Atypical teratoid/rhabdoid tumor (AT/RT)		Loss: 22/22q {S}, though a subset of AT/RT-like tumors retain 22q	Classic AT/RT: SMARCB1 mutation/deletion/exonic duplication in 98% of tumors, or (rarely) SMARCA4 inactivation {all W} Three molecular classes: TYR: ~ 75% show broad 22q loss that includes SMARCB1 SHH: ~ 50% lack any SMARCB1 copy number aberration; ~ 25% have focal SMARCB1 aberrations MYC: ~ 75% show focal SMARCB1 loss	Most cases occur before 3 yrs of age TYR subclass: mostly infratentorial SHH subclass: supra/infratentorial MYC subclass: mostly supratentorial	25060813; 23074045; 26109171; 25016934; 26923874
Embryonal tumor with multilayered rosettes, C19MC-altered		ETMR (incl. ETANTR): Gain: 2, 7q, 11q {all S} Loss: 6q {S}	Amplification: miRNA cluster C19MC at 19q13.42 {W}	Occurs mainly in children < 4 yrs old	24839957; 24470553; 24337497; 22324795; 20407781, 19057917 WHO CNS Tumors (2016)
Embryonal tumor, other		CNS NB-FOXR2 group: 1q gain, 16q loss, polysomy 8 CNS EFT-CIC group: polysomy 8 CNS HGNET-MN1 group: 16q loss, polysomy 8 CNS HGNET-BCOR group: mostly balanced genomes	CNS NB-FOXR2 group: JMJD1C fusions, FOXR2 fusion or deletion CNS EFT-CIC group: NUTM1 rearrangement/fusion, CIC rearrangement CNS HGNET-MN1 group: MN1 rearrangement CNS HGNET-BCOR group: BCOR intragenic tandem duplication	Most common in children, but may also occur in adolescents and adults	26919435; 22691720; 22772606; WHO CNS Tumors (2016)

(*continued on next page*)

Table 1 (*continued*)

PEDIATRIC TUMORS	SUBTYPES	BROAD ABERRATIONS (> 10Mb)	FOCAL ABERRATIONS (< 10 Mb)	CLINICAL FEATURES	REFERENCES (PMID/PMCID)
CHOROID PLEXUS TUMORS (CPT)	Choroid plexus papilloma (CPP, WHO grade I) and atypical choroid plexus papilloma (WHO grade II)	Hyperdiploidy {S} Loss: rare, no recurrent losses	No diagnostic mutations/events	CPP and aCPP likely belong to same molecularly defined entity; CPP is a diagnostic feature of Aircardi syndrome	WHO CNS Tumors (2016) 23172371; 25575132; 25336695; 11891207
	Choroid plexus carcinoma (CPC, WHO grade III)	Aneuploidy (including both hypo- and hyperdiploidy types of CPC); frequent copy neutral LOH, particularly involving chromosome 17 Gain: 1, 7, 12, 20 in > 80% of hyperdiploid CPCs Loss: 3 (in all hypodiploid CPC), 6, 11, 12q, 16, 22	Mutation: TP53 in > 50% {S} Amplification: PDGFRB	80% occur in children; associated with Li-Fraumeni syndrome; Lack of SMARCB1/SMARCA4 aberrations can be used to distinguish CPC from AT/RT	24478045; 21990040; 25575132; 18157090; 25336695

Table 2
Genomic aberrations in adult primary CNS tumors.

ADULT TUMORS	SUBTYPES	BROAD ABERRATIONS (>10Mb)	FOCAL ABERRATIONS (< 10 Mb)	CLINICAL FEATURES	REFERENCES (PMID/PMCID)
GLIOMAS Low grade gliomas, WHO grade I-II					
	Pilocytic astrocytoma	Gain: 5, 7, 6, 11 Loss: 1, 2, 3, 13, 14, 16, 17, 19	Fusion: KIAA1549-BRAF fusion (via 3′BRAF duplication) {D}, other BRAF partners reported; NTRK fusions (rare) Mutation: BRAF V600E {D} FGFR1	Aneuploidy is more predominant in adult PA; Infratentorial tumors more likely to have BRAF fusion and be negative for BRAF mutation; Extra-cerebellar tumors are more likely to be BRAF V600E+ but negative for BRAF fusion; Surgical resection can be curative	24470550; 26378811; 25664944; 26992069; 29466156; https://www.fda.gov/Drugs/InformationOnDrugs/ApprovedDrugs/ucm626720.htm.
	Pleomorphic xanthoastrocytoma (PXA)	Gain: 7, 2, 5, 21, 20, 12, 15 Loss: monosomy 9 / 9p; Deletions: 10, 13, 14, 22 CN-LOH: 9p, 22	Loss: homozygous loss CDKN2A/B {S} Mutation: BRAF V600E {D}	Adults and pediatric tumors show similar CNVs; CDKN2A/CDKN2B loss may correlate with anaplastic histology	23442159; 28181325
	Ganglioglioma	Gain: polysomy 5, polysomy 7, 10p Loss: 1p loss, monosomy 9 (with focal CDKN2A loss)	Loss: CDKN2A/B Mutation: BRAF V600E {D}, TSC1, TSC2, FGFR1, FGFR2, KRAS	Generally indolent tumors; surgical resection can be curative	23442159; 25764012; 29880043
	Angiocentric glioma	Loss: 6q24-q25	Fusion: MYB-QKI rearrangement/deletion {S} (classic histology) Rearrangement: MYB alone (atypical histology) Amplification: MYB (atypical histology)	Generally indolent tumors; surgical resection can be curative	26829751; 28803398

(*continued on next page*)

Table 2 (*continued*)

ADULT TUMORS	SUBTYPES	BROAD ABERRATIONS (>10Mb)	FOCAL ABERRATIONS (< 10 Mb)	CLINICAL FEATURES	REFERENCES (PMID/PMCID)
Infiltrating Gliomas	Dysembryoplastic neuroepithelial tumor (DNET)	No specific changes	Mutation: intragenic duplication or mutation FGFR1; BRAF V600E	Rare in adults; Benign with excellent prognosis even with subtotal resection	26920151; 23442159; 21937911
	Rosette forming glioneuronal tumor	Gain:1q, 7, 9, 16 Loss: 1p Amplification: 9q34.2, 19p13.3	Mutation: PIK3CA, FGFR1 {S}	Generally indolent tumors; surgical resection can be curative	27893178; 26371886
	Diffuse astrocytoma/anaplastic Astrocytoma, WHO grade II/III, IDH mutant	Gain: 4q, 7q, 8q24, 12q Loss: 9p, 19q (without 1p)	Gain: MYC Loss: CDKN2A/B, PML15q22 Mutation: IDH1/2 {W}, TP53 {D}, ATRX {D}	Better prognosis than IDH wildtype astrocytoma; Progression to grade IV often involves loss of 10q, gain of CDK4, CDK6, CCNE2, and an increase in overall copy number alterations.	26824661; 26061753; 25263767; 26061754; 28535583; 26091668; 25701198; 26865861; 29687258
	Diffuse astrocytoma/anaplastic astrocytoma, WHO grade II/III, IDH wild-type	Gain: 7, 19 Loss: 4, 9p 10 Amplification: EGFR, MDM4, CDK4	IDH-WT {W}	Poor prognosis with similar abnormalities to glioblastoma	26061754; 26824661; 28535583; 26091668; 26810070
	Oligodendroglioma/ anaplastic oligodendroglioma, WHO grade II/III	Rearrangement: der(1;19)(q10;p10) leads to 1p/19q co-deletion {W} Loss: 1p/19q {W}, 9p, 14q, less frequent 4, 18q	Gain: MYC Loss: MAX (14q), FBXW7, CDN2KA/B Mutation: IDH1/2 {W}, FUBP1, CIC, TERT promoter, NOTCH1, PIK3CA or PIK3R1	Activation of MYC pathway is often seen with loss of 9p (CDKN2A/B), and 14q (MAX gene) and is reported to have a worse prognosis	27090007; 26061753; 25263767; 26061754; 24335697; 25664944; 26061753; 26941959; 26824661; 26061751

(*continued on next page*)

Table 2 (*continued*)

ADULT TUMORS	SUBTYPES	BROAD ABERRATIONS (>10Mb)	FOCAL ABERRATIONS (< 10 Mb)	CLINICAL FEATURES	REFERENCES (PMID/PMCID)
	Glioblastoma (GBM), grade IV IDH mutant	Gain: 1/1q, 6p Loss: 3p, 10, 13, 14, 15, 22 (3, 4q, 19q, 16p, 21q, 5p loss in age <40) Amplification: CDK6, cyclin E2, CDK4, MET Chromothripsis	Gain/Amplification: CDK4, CDK6, cyclin E2 Loss: PTEN Mutation: IDH1/2 {W}, TP53 {D}, ATRX {D}	Account for ~ 10% of GBM; correspond closely to secondary GBM (presumed evolution from prior glioma). These cases often involve loss of 10q, gain of CDK4, CDK6, CCNE2, and increase in copy number alterations.	26061754; 25754088; 28535583; 25931051; 26091668; 25461780; 27157931; 25727226; 26323991; 26061751; 29687258
	Glioblastoma (GBM), grade IV IDH wildtype	Loss: 9p, 10, 4, 13, 14, 15, 22, (3, 4q, 19q, 16p, 21q, 5p loss in age <40) Gain: 7, 19, 20; (1q, 12p, 11q, 9q, 4, 10p gain in age <40) Amplification: EGFR {D}, MDM4, CDK4, MET	Loss: homozygous CDKN2A/B, PTEN, RB1 IDH-WT {W} Mutation: TERT promoter {D}, EGFR, PTEN, NF1, TP53, PDGFRA, RB1, PIK3CA or PIK3R1 Amplification: EGFR {D}, MDM4, MDM2, CDK4, PDGFRA, MET	Overal poor prognosis. Gain of 19q, amplification of EGFR, and homozygous loss of CDKN2A are seen primarily in patients over age 40. Polysomy of both chromosomes 19 and 20 may be associated with longer survival.	26061754; 25754088; 28535583; 25931051; 26091668; 25461780; 27157931; 25727226; 26061751
MENINGIOMA					
	Grade 1	No copy number changes in 44% Gain: multiple polysomies, 5 Loss: 22/22q- common as sole aberration {S} CN-LOH: 1p, 14q	Loss: NF2, CDKN2A, PTEN Mutation: NF2 {S}, PI3K, SMO {S}, AKT1{S}, KLF4{S}, TRAF7{S}, TERT, ARID1A	Array findings characteristic of higher grade tumors when histology supports lower grade may suggest increased likelihood of recurrence. Polysomy, particularly involving chromosome 5, are seen in angiomatous meningiomas. LOH 1p and/or LOH 1p/14q correlated with anaplastic transformation.	23528542; 27575681; 20015288; 21988727; 19918127; 25347344; 23334667; 25963524; 26826201; 28195122; 26323607; 11958368; 25965831; 24536048; 24722350; 12568317; 26771848; 27012381; 27480481; 27624470; 27624470; 27458586; 25347344; 17225936

(*continued on next page*)

Table 2 (*continued*)

ADULT TUMORS	SUBTYPES	BROAD ABERRATIONS (>10Mb)	FOCAL ABERRATIONS (< 10 Mb)	CLINICAL FEATURES	REFERENCES (PMID/PMCID)
	Grade 2 atypical	Gain: 1q, 9q, 12q, 15q, 17q, 20q {all S} Loss: 1p, 6q, 10, 14/14q, 18/18q, 22/loss 22q; {all S}	Loss: NF2 {S}, CDKN2A, PTEN, Mutation: NF2 {S}, CDKN2A/C, SMARCE1 {S}, SMARCB1, TERT {S}	Gain of 1q is assocociated with a shorter progression free survival (PFS); Loss of 1p, 9p and 10 appear with greater frequency as tumor grade increases.	23528542; 27575681; 20015288; 21988727; 19918127; 25347344; 23334667; 25963524; 26826201; 28195122; 26323607; 11958368; 25965831; 24536048; 24722350; 12568317; 26771848; 27012381; 27480481; 27624470; 27624470; 27458586; 25347344; 17225936
	Grade 3 anaplastic	Gain: 1q, 9q, 12q, 15q, 17q23, 20q {all S} Loss: 1p, 6q, 9p, 10, 14/14q, 18/18q, 22/loss 22q {all S}	Loss: NF2 {S}, CDKN2A, PTEN Mutation: NF2{S}, CDKN2A/C, TERT {S} Amplification: RPS6K in higher grades {S}	Loss of 9p and amplification/gain of 17q23 more frequent than other abnormalities. Gain of 1q is associated with a shorter PFS; Loss of 1p, 9p and 10 appear with greater frequency as tumor grade increases.	23528542; 27575681; 20015288; 21988727; 19918127; 25347344; 23334667; 25963524; 26826201; 28195122; 26323607; 11958368; 25965831; 24536048; 24722350 12568317; 26771848; 27012381; 27480481; 27624470; 27624470; 27458586; 25347344; 17225936

(*continued on next page*)

Table 2 (*continued*)

ADULT TUMORS	SUBTYPES	BROAD ABERRATIONS (>10Mb)	FOCAL ABERRATIONS (< 10 Mb)	CLINICAL FEATURES	REFERENCES (PMID/PMCID)
EPENDYMOMA (in order of increasing WHO grade)		DNA-based methylation classifies tumors across anatomical sites — intracranial (posterior fossa or supratentorial) or spinal — and across tumor grades and age groups	Fusion: RELA fusion {W} YAP1 fusions (supratentorial tumors) {D} Mutation: NF2 (spinal tumors) {S}	Intracranial (in children, 90%) or spinal tumors; Histological distinction between WHO grade II and III is not reliable; Prognostic differences among tumors suggested on the basis of methylation analysis	WHO CNS Tumors (2016) 25965575; 21627842; 24939246; 22516549
	Classic ependymoma (no WHO grade assigned)	Gain:1q, 5, 7, 9, 11, 18, 20 {all S} Loss: 1p, 3, -6/6q, 9p, 13q, 17, 22 {all S}	Loss: CDKN2A/CDKN2B (supratentorial); NF2 {S} Mutation: NF2 (esp. in spinal tumors) {S}	Usually intracranial, spinal tumors (myxopapillary) are rare; 80% of pediatric tumors develop in posterior fossa (PF); Supratentorial tumors preferentially show monosomy 9; 1q gain is unfavorable prognostic indicator in PF tumors; spinal tumors associated with NF2 mutation (germline)	25965575; 22338015; 28371821; 19531565
	Subependymoma, WHO grade I (intracranial or spinal)	Typically balanced genomes Loss: -6/6q in spinal tumors {S}	No diagnostic mutations	Favorable prognosis	21959044; 21840481 WHO CNS Tumors (2016)

(*continued on next page*)

Table 2 (*continued*)

ADULT TUMORS	SUBTYPES	BROAD ABERRATIONS (>10Mb)	FOCAL ABERRATIONS (< 10 Mb)	CLINICAL FEATURES	REFERENCES (PMID/PMCID)
	Myxopapillary ependymoma, WHO grade I (spinal)	Aneuploidy: multiple chromosome gains {S}	Mutation: NF2 (including germline) in spinal tumors	More common in adults	25965575; 3991130; 20425037; 25957288; 25965575; 22516549
	Ependymoma, RELA fusion-positive, WHO grade II or III (intracranial)	Gain: 1q Aneuploidy: multiple chromosome losses and gains Chromothripsis: chromosome 11 (70% of supratentorial tumors) {S}	Fusion: c11orf95-RELA (supratentorial tumors) {W} Loss: CDKN2A/B (may help distinguish from other supratentorial ependymomas)	Unfavorable prognosis	25965575; 24553141; 28371821
	Anaplastic ependymoma (no WHO grade assigned; intracranial or spinal)	Epigenetic studies suggest range of abnormalities; tumors may show balanced or unbalanced genomes	Mutation: NF2 (including germline) in spinal tumors Fusion: RELA fusion, YAP1 fusions can correspond to anaplastic histology	Mostly intracranial tumors, rarely in spinal cord	25965575; 27022130

Integrated interpretation

At many of our institutions, weekly interdisciplinary case review conferences have been in place for some time. Benefits of these regular discussions include: (1) providing opportunities for diagnosticians across disciplines (genetics, neuro-oncology, neuropathology) to be aware of relevant literature, (2) providing a regular time to be updated about clinical trials available to patients and the requisite CMA findings that can determine eligibility, and (3) obtaining follow up clinical details for patients, including discussion of CMA analysis of recurrent tumors, and (4) providing a forum to ensure uniformity in reporting, including how best to describe clinical significance of aberrations or whether an abnormality may be inherited rather than acquired [31,122]. Turnaround times will vary among laboratories but often range from seven to fourteen days, depending on how often samples are batched by the laboratory, with seven days being a reasonable timeframe to respond to requests identified as requiring rush processing.

Overview of pathological and genomic features of CNS tumors

Below, we give brief synopses of a selection of the most common primary CNS lesions analyzed genomically, with a focus on relevant copy number aberrations further explored in the accompanying tables. Salient clinical and pathological data are summarized with a particular focus on entities that may prove difficult to distinguish by traditional histologic analysis; these data are provided with an eye toward informing cytogeneticists and molecular pathologists of known histopathologic limitations encountered in common referral diagnoses.

Infiltrating gliomas

Infiltrating gliomas – those with the capacity to invade the brain parenchyma as single cells and frustrate clinical efforts at local control – display somewhat different behaviors and genomic backgrounds in adult and pediatric patients [3]. Infiltrating gliomas in adults are principally defined by the presence or absence of isocitrate dehydrogenase 1 or 2 (*IDH1/2*) mutations [3,64,91]. This particular criterion has been accepted as a means of tumor classification; the WHO naming convention for infiltrating gliomas includes the mutation status in the tumor names. IDH-mutant infiltrating gliomas include both oligodendrogliomas and IDH-mutant infiltrating astrocytomas, whereas adult IDH-wildtype infiltrating gliomas are mostly restricted to classification as IDH-wildtype infiltrating astrocytomas [64]. These distinctions are not merely relevant for correct diagnostic characterization; they also carry tremendous prognostic weight. In general, IDH-mutant infiltrating gliomas behave in a more indolent fashion and exhibit better responses to conventional therapy than their IDH-wildtype counterparts [74]. Beyond IDH mutation status, characterization of these tumors is well-informed by assessment of copy number abnormalities ([64]; Tables 1 and 2).

Oligodendroglioma, IDH mutant, 1p/19q-codeleted

The 2016 WHO update codified the well-established understanding that oligodendrogliomas are best classified as adult IDH-mutant infiltrating gliomas with a whole-arm co-deletion of chromosome arms 1p and 19q. Under the 2016 WHO guidelines, diagnosis of an oligodendroglioma requires documentation of both an IDH mutation and a 1p/19q whole-arm co-deletion [64]. The exact WHO grade is based upon identification of additional histologic parameters. Using this framework, the potential for misdiagnosis of these tumors is minimized, as previously some oligodendrogliomas were characterized as oligoastrocytomas (now a disfavored term) based upon the histologic interpretation of an astrocytic appearance within the tumor. Furthermore, using the previous schema, some IDH-wildtype infiltrating gliomas were mistakenly labeled as oligodendrogliomas or glioblastomas with an oligodendroglial component (another now-disfavored term) due to the observation of oligodendroglial features in an otherwise high-grade neoplasm [64,91,101].

Most importantly, the whole-arm co-deletion of 1p and 19q in IDH-mutant oligodendroglioma arises through a whole arm translocation followed by subsequent loss of the derivative chromosome that includes 1p and 19q [28,41,47,113]. This genomic imbalance is readily detected by CMA (Fig. 1A). Other modalities, such as fluorescence *in situ* hybridization (FISH), were previously utilized but have significant limitations. Namely, the targeted nature of FISH could lead to misclassification of tumors with only partial, typically distal, 1p and 19q losses [111]. In addition, ploidy changes and section artifact are two contributing factors that could complicate interpretation of some tumors [45]. Correct identification of the whole arm co-deletion and the resulting genetic classification of oligodendroglial tumors is of utmost importance, as oligodendrogliomas are typically slowly progressive tumors that respond well to conventional therapy [64]. Hence, evaluation of the 1p/19q co-deletion through a whole genome assay is critical to both diagnosis and prognosis of these tumors.

Infiltrating astrocytoma, IDH-mutant

Diffuse infiltrating gliomas with *IDH* mutations, alterations in *ATRX* and *TP53*, and lacking a whole-arm 1p/19q co-deletion are classified as diffuse astrocytomas, *IDH*-mutant, under the 2016 WHO schema. Further grading under the current WHO guidelines is accomplished by assessment of histologic features not addressed here; notably, this general category of neoplasm includes the entities “diffuse astrocytoma, *IDH*-mutant (WHO grade II)” and “anaplastic astrocytoma, *IDH*-mutant (WHO grade III).” The mean age of incidence for these *IDH*-mutant astrocytomas is 36-38 years; the histologic distinction of grade II and grade III tumors can be challenging in some cases [64,109]. Accurate prediction of the behavior of tumors in this general category is a topic of intense current interest and research, as histologic grading alone has not proven as useful. Copy number analysis as well as mutation detection or methylation analysis may play a role in prognostication of *IDH*-mutant astrocytomas. The delineation of homozygous *CDKN2A* (p16) loss (9p21.3) seems particularly helpful in elucidating aggressive behavior in these tumors, and other changes such as *CDK4* amplification (12q14.1) or the total number of copy number aberrations detected may also be relevant in this regard [23,64,73,100,109]. Indeed, a cIMPACT-NOW publication states that, in the setting of an IDH mutant astrocytoma, homozygous *CDKN2A* loss should elevate a tumor to the level of a grade 4 neoplasm. [14]. While a diagnostic copy number signature for *IDH*-mutant astrocytoma does not exist, common changes include broad gains (often larger than 10 Mb) involving 7q, 8q, 10p, and 12p. Compared with histologically defined grade II *IDH*-mutant astrocytomas, the grade III tumors more frequently show 9p and 19p losses; targeted amplifications are occasionally identified, as described in Tables 1 and 2 [12,28,53,88,117].

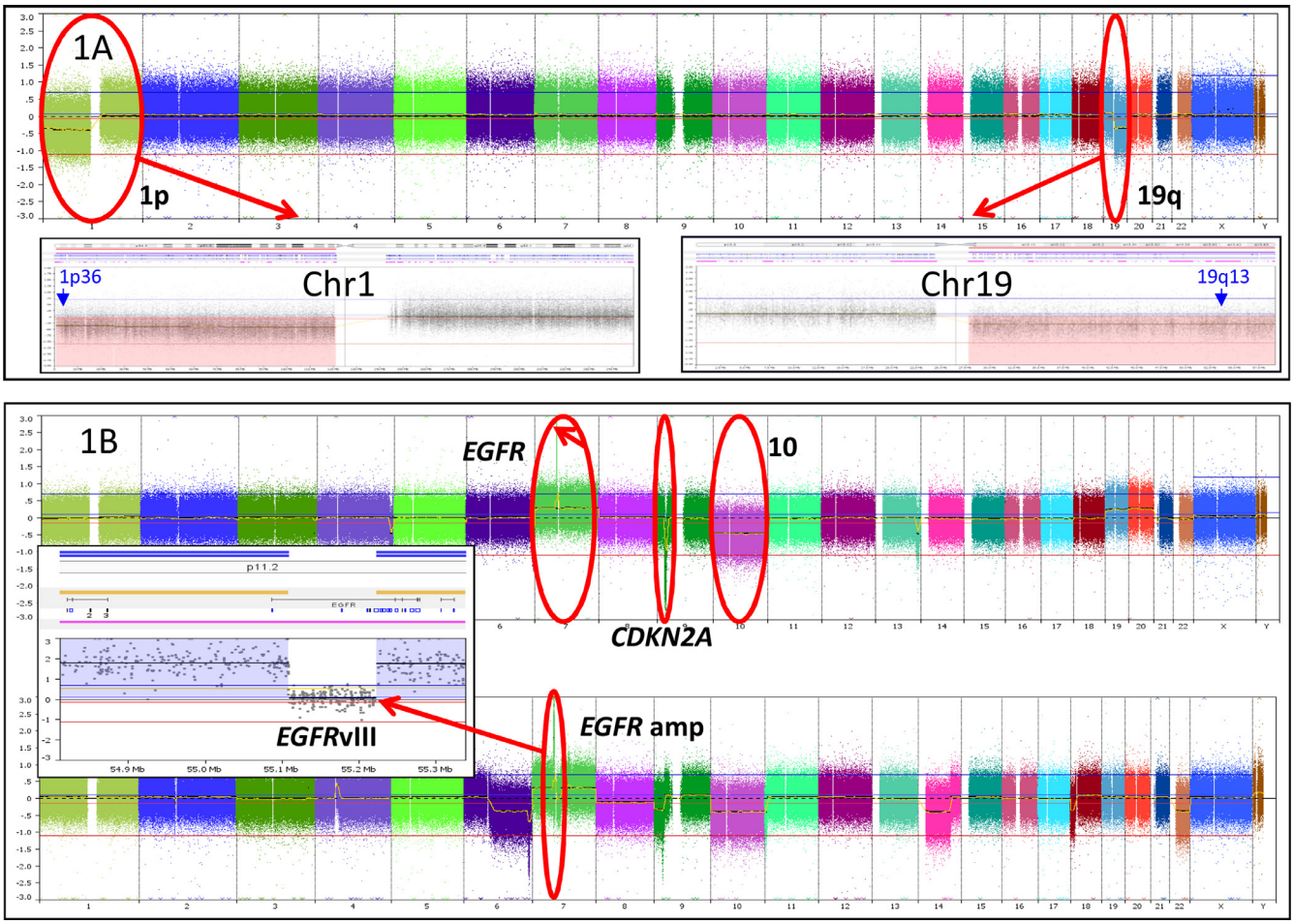

Fig. 1. Whole genome view of CNVs detected in brain tumors by CMA. A. Whole arm loss of 1p and 19q in an IDH-mutant infiltrating glioma, consistent with the expected copy number profile of an oligodendroglioma. Of note, these particular 1p and 19q losses are best identified by CMA as they can be misinterpreted by assays that do not evaluate whole chromosome arms. Blue arrows show the positions of FISH probes for 1p/19q. **B.** Top: typical CNVs identified in an IDH-wildtype glioblastoma, including: *EGFR* amplification (7p11.2; arrow); homozygous loss of *CDKN2A/B* (9p21.3); and monosomy 10, leading to single copy loss of *PTEN*. Bottom**:** an IDH wildtype glioblastoma showing *EGFR* amplification and an intragenic deletion of *EGFR* known as the *EGFR*vIII variant.
Infinium CytoSNP-850K Beadchip (Illumina)(For interpretation of the references to colour in this figure legend, the reader is referred to the web version of this article.)

Regardless, accurate diagnosis of an *IDH*-mutant infiltrating astrocytoma requires not only demonstration of an *IDH* mutation but also documentation of additional genomic findings. Alterations such as an *ATRX* mutation, loss of ATRX expression, or a mutation in *TP53* can serve to positively reinforce the diagnosis of these tumors in the correct histological context. Documentation of the absence of a 1p/19q co-deletion is critical in the diagnostic workup of *IDH* mutant infiltrating gliomas that are not straightforward in terms of prior combined histologic and genomic assessment [65].

Glioblastoma, IDH-mutant

These tumors are *IDH*-mutant infiltrating astrocytomas that have developed cardinal histologic features of GBM (tumor necrosis and/or proliferative vasculature). Hence, overall, they exhibit genomic features of an *IDH*-mutant infiltrating astrocytoma, i.e. they lack a whole-arm 1p/19q co-deletion and usually display alterations in *ATRX* and *TP53*. As there is histologic overlap between anaplastic oligodendrogliomas (i.e., *IDH*-mutant and positive for 1p/19q co-deletion) and *IDH*-mutant GBM (including necrosis and vascular proliferation), it is important to exclude the presence of a 1p/19 co-deletion when establishing the diagnosis of IDH-mutant GBM. A specific CNA profile is not established for IDH-mutant GBM [64].

Infiltrating astrocytoma, IDH-wildtype

As a group, these infiltrating gliomas are relatively heterogeneous and may not be readily subclassified by histologic methods alone. From a genomic perspective, several adult tumor types can be appropriately described as *IDH*-wildtype infiltrating glioma. Some of these gliomas show genomic changes most like that of an *IDH*-wildtype GBM (see below); identification of such alterations is critical because these tumors likely will display aggressive behavior despite lacking the necessary histologic features to support that diagnosis [13]. Another tumor type, the *H3K27M*-mutant tumors, is characterized by mutations in histone variant genes, such as *H3F3A* and *HIST1H3B*. As further described below, these tumors typically arise along the midline structure, were originally characterized in the pediatric population (formerly known as diffuse intrinsic pontine glioma, DIPG), but can also occur in adults [64,125]. However,

histologically they are heterogeneous as not all tumors show high-grade features. Finally, some diffusely infiltrative astrocytomas can show genomic changes similar to those identified in poorly infiltrative, low-grade gliomas such as pilocytic astrocytomas or angiocentric gliomas [64]. As this latter category of *IDH*-wildtype astrocytoma is more commonly described in the pediatric population, it is described further under the section on low-grade gliomas, below.

Certainly, initial characterization of this group of tumors requires histologic diagnosis as well as evaluation for an *IDH* mutation. Genomic analysis may inform further sub-classification through interrogation of CNA, gene fusions, and mutations. For instance, CMA analysis of a histologically diagnosed *IDH*-wildtype diffuse astrocytoma may show polysomy 7, *EGFR* amplification, homozygous *CDKN2A/B* loss, and monosomy 10. These changes are the same as those often seen in IDH-wildtype GBM, and recent publications have allowed for some of these aberrations to be used to apply a diagnosis of "molecular features of glioblastoma" [13]. Namely, a diffusely infiltrative astrocytic tumor that is proven to be IDH-wildtype can be designated as a "diffuse astrocytic neoplasm with molecular features of glioblastoma" if it is also shown to have an *EGFR* amplification, *TERT* mutation, or combination of polysomy 7 with whole chromosome 10 loss. This relatively recent change in approach results from efforts of the c-IMPACT NOW group, made up of an expert panel convened to recommend updates to diagnostic criteria based upon incorporation of literature published in between WHO editions [13].

In pediatric patients, diffuse astrocytomas often show a distinct genomic profile from that typically detected in adults. Pediatric-type diffuse astrocytomas have been shown to harbor a variety of different abnormalities, including *MYB* amplification or rearrangement, *MYBL1* truncating rearrangements or tandem duplications, *BRAF* V600E mutations, and alterations of *FGFR1*. High-grade pediatric gliomas are more likely to be wildtype for *IDH* mutations [3,64,95,123].

Glioblastoma, IDH-wildtype

Glioblastomas (GBMs) have been the subject of extensive study for many decades, as they are extremely aggressive and almost uniformly deadly tumors that show only limited response to therapy. As a result, GBM has been a top target for study by genome-wide assays, and The Cancer Genome Atlas (TCGA) project and other efforts have produced considerable documentation of the hallmark genomic abnormalities observed in GBMs, including some of the first descriptions of *IDH* mutations in infiltrating gliomas [12,15]. Building on these investigations, it became apparent that *IDH* mutations define separate forms of infiltrating glioma, as described above. Amongst the IDH-wildtype GBMs (i.e., those lacking an *IDH* mutation), however, these analyses also showed some shared features in addition to the genomic complexity befitting a high-grade malignancy in the adult population. However, from a clinical standpoint, assignment of a GBM subtype is not as clinically relevant as detection of an *IDH* mutation [64]. Here, we briefly review the cardinal CNA most commonly seen in *IDH* wildtype glioblastomas.

IDH-wild type GBMs show polysomy 7, 9p21.3 loss (*CDKN2A*) and monosomy 10, which leads to loss of *PTEN* (Fig. 1B). Typical focal copy number abnormalities include oncogene amplifications and tumor suppressor deletions. In GBM, oncogenes commonly amplified include *PIK3C2B, MDM4, PDGFRA, EGFR, CDK6*, MET, *CDK4*, and *MDM2*; these aberrations may represent avenues for targeted therapy [64]. Of significance is *EGFR*, a receptor tyrosine kinase that is amplified in approximately 40% of primary GBMs but is an atypical finding in secondary GBMs (i.e., those GBMs evolving from a lower grade glioma) most of which are IDH-mutant ([15,78,79]). *EGFR*-amplified GBMs are most commonly *IDH*-wildtype and represent a subset of GBMs characterized by abnormalities in receptor tyrosine kinase-driven pathways. Numerous tumor suppressors also are affected via copy number loss in GBM, including *CDKN2A, CDKN2B, PTEN, RB1*, and *NF1*. Likewise, *PTEN* (10q23.31), *RB1* (13q14.2), and *NF2* (22q12) are putative targets of the whole-chromosome losses, while *CDKN2A and CDKN2B* are often focally, homozygously deleted (Fig. 1B). Other tumor suppressor genes targeted by CNA in GBM include *NF1* and *TP53*. Interestingly, tetraploidy has been identified in 10% of GBM. Although tetraploid tumors are more likely to carry *TP53* mutations, no correlations between tetraploidy and clinical outcome have been observed and therefore the significance of this finding is unknown [15,79,97,126]. It is important to note again that tetraploidy can be identified only by SNP CMA analysis and not by aCGH.

A subset of *EGFR*-amplified GBMs will also harbor an intragenic deletion of *EGFR* encompassing exons 2-7, also known as the *EGFR*vIII variant which occurs in 20-50% of GBM with amplified *EGFR* [10,15] (Fig. 1B). The resulting deletion of the extracellular domain leads to a truncated receptor with constitutive tyrosine kinase activity [37]. While initially believed to represent a tumor-specific therapeutic target in GBM, it is unclear whether prognosis is impacted when this variant is identified [129]. In contrast, other structural variants of *EGFR* have been described that are thought to adversely impact protein function [35,43,85]. Similarly, tumor suppressor genes such as *CDKN2A/B, PTEN, TP53*, and *RB1* are targeted both by CNA and mutations that lead to hypomorphic or null alleles.

Fusion events have also come to be increasingly recognized as important in driving oncogenesis in a small subset of GBMs; in particular the most recognized structural events, predominantly in *IDH*-wildtype GBM, are *FGFR3-TACC3* fusions that result in constitutive kinase activity and therefore confer sensitivity to FGFR tyrosine kinase inhibitors [27,60,112] (Supplementary Fig. 1). While the presence of a *FGFR3-TACC3* fusion may be suggested by CMA findings, the ability to detect these types of variants depends on the probe coverage and quality of the array data.

Several differences in CNAs between adult and pediatric GBM have been described. Notably, the most common amplicon in pediatric high-grade gliomas includes *PDGFRA*, rather than *EGFR*. In addition, pediatric GBM are more likely to show 1q gain and less likely to show polysomy 7 and 10q (*PTEN*) loss. In contrast to adult GBM, the pediatric counterparts do not show canonical *IDH* mutations. Interestingly, a subset of pediatric high-grade gliomas shows very few CNAs [39,88,98].

A wide variety of assays would be necessary to detect all the known genomic abnormalities in a tumor as biologically complex as GBM. However, whole genome CMA allows detection of the cardinal copy number abnormalities, findings that in concert with *IDH* mutation testing facilitate tumor classification. Some copy number abnormalities may also be relevant for clinical trial placement.

H3 K27M mutant tumors

These infiltrative gliomas with a K27M mutation in *H3F3A* or *HIS1H3B/C* are primarily of astrocytic lineage and typically arise along midline structures [64]. 20% show recurrent activating mutations in *ACVR1* [16,118]. They are observed more frequently in children than in adults and are marked by aggressive clinical

behavior. Histologically they are a diverse group, with 10% meeting criteria for WHO Grade II tumors and the remainder classified by light microscopy as higher grade. As such, the histologic impression may not accurately predict clinical outcomes. To reflect the distinctive features of these group of tumors a new entity, diffuse midline glioma, H3 K27M-mutant was instituted that is WHO Grade IV by definition [64]. As further evidence of this, a study evaluating the prognostic utility of H3 K27M mutation as an independent predictor in pediatric high-grade glioma concluded presence of the mutation is a poor prognostic indicator for survival [67].

Whole genome CMA of K27M-mutant gliomas reveals *PDGFRA* amplifications in as many as half of all cases [64,93]. Other common amplifications include *MYC* or *MYCN, CDK4, CDK6, CCND1-3* and *MET*. Deletions involving tumor suppressor genes are unusual and fusions between *FGFR1* and *NTRK* genes have also been identified. Perhaps surprisingly, approximately one-fifth of these tumors can be relatively copy number neutral [16,125].

Low grade gliomas

Low grade gliomas (LGG), are also described as low grade neuroepithelial tumors to highlight the presence of both glial and neuronal differentiation. LGG comprise a category of tumors that are usually well-circumscribed, show little infiltration of the surrounding brain, display generally indolent behavior, and may be amenable to cure by surgical resection. Most are WHO grade I, though some can be higher grade. Many of these lesions are more commonly seen in children, though they also occur in the adult population. From the genomic perspective, they are often typified by a single abnormality or small number of changes in a quiescent background. Detection of these typical abnormalities can greatly assist in diagnosis of these lesions, particularly in terms of distinguishing them from “true” infiltrating or higher-grade gliomas that would display different behavior and necessitate more aggressive therapy. In addition, some of the abnormalities seen in these lesions are potentially druggable, placing extra emphasis on discovery of these changes in cases that are recurrent or not readily resectable [94,127].

Pilocytic astrocytomas

Classic pilocytic astrocytomas (PA) are low-grade (WHO Grade I) gliomas that typically develop in the cerebellum and represent the most common glioma arising in children. Generally, PA are indolent lesions for which surgical resection can be curative. Histologically, PA show a classic biphasic pattern, Rosenthal fibers and eosinophilic granular bodies [64] and, on occasion, may be confused with higher grade gliomas. Molecularly, the clear majority show a tandem duplication at 7q34 involving gain of a 1.9 Mb segment with breakpoints disrupting *BRAF* and *KIAA1549* [49,110]. Because of this duplication, 5’*KIAA1549* is fused to 3’*BRAF* and gives rise to a novel chimeric protein with a constitutively active kinase domain [51]. Assuming sufficient probe resolution, this genomic gain can be identified by whole genome CMA analysis (Fig. 2). *KIAA1549-BRAF* fusion is not restricted to classic PA, but also extends to PA that develop along the optic pathway (i.e., optic gliomas such as those seen in neurofibromatosis type 1) and elsewhere [32,103]. Furthermore, while the *KIAA1549-BRAF* fusion is the most common structural aberration in PA, additional varieties of *BRAF* rearrangements, including translocations, have also been described in low-grade gliomas [24,105]. Of note, PA are not unique to the pediatric population and can also be diagnosed in adults, in whom copy number analysis is more likely to identify not only the *KIAA1549-BRAF* fusion but also polysomy of multiple chromosomes [34,49].

Pleomorphic xanthoastrocytomas

Pleomorphic xanthoastrocytoma (PXA) is a WHO grade II tumor that has a greater tendency toward recurrence and aggressive behavior than other low grade neuroepithelial tumors. Rarely, PXA may exhibit anaplastic histologic features that correspond to a WHO grade III designation and even more aggressive behavior. PXA typically display enlarged, atypical astrocytic cells, some of which contain foamy, or xanthomatous, cytoplasm against a background of eosinophilic granular bodies and chronic inflammation. Some of these microscopic features overlap with other disease categories, and in particular PXA can mimic glioblastoma and other infiltrating gliomas histologically [64]. From a molecular perspective, PXA carry a high incidence of *BRAF* alterations, particularly V600E mutations, as well as abnormalities involving chromosome 9 that include homozygous deletion of *CDKN2A* and *CDKN2B* [64,90,121].

Gangliogliomas

Gangliogliomas (GG) arise in many areas of the CNS, though most commonly in the temporal lobe. They are characterized by the presence of a dysplastic abnormal neuronal component as well as a morphologically variable glial component; hence, they are considered a type of glioneuronal tumor. While these WHO grade I tumors are typically slow-growing and well-delineated, patients also may present with seizures. Rarely, GG can also show anaplastic features that portend worse behavior [64]. Similar to PXA, a substantial portion of GG carry *BRAF* V600E mutations [106]. In addition, a variety of other BRAF mutations or fusions as well as alterations to genes involved in the MAP kinase pathway have been documented. While entirely characteristic copy number aberrations are not known in GG, gain of chromosome 7 seems to be the most common cytogenetic abnormality [64,89,92].

Dysembryoplastic neuroepithelial tumors

Another variant of a glioneuronal tumor is a dysembryoplastic neuroepithelial tumor (DNT or DNET). DNT typically display a proliferation of small, oligodendrocyte-like cells in a background of bluish, myxoid substance deposition. These WHO grade I tumors are not aggressive and rarely progress to form higher grade lesions, though they may be associated with seizure activity [64]. A variety of genomic abnormalities have been described in DNT, including *BRAF* mutations (particularly V600E) and *FGFR1* alterations [22,61,64,94].

Rosette-forming glioneuronal tumors

Originally described adjacent to the fourth ventricle, rosette-forming glioneuronal tumors (RGNT) have since been found in other areas of the CNS. This type of glioneuronal tumor shows microscopic features that overlap with other low grade neuroepithelial tumors, particularly pilocytic astrocytomas. However, these tumors are distinguished by neurocytic tumor cells that form small rosette structures [64]. Though RGNT are rare, studies to date have described mutations in *FGFR1* and/or *PIK3CA* in these neoplasms ([29,38,64]; Sievers P et al., 2019).

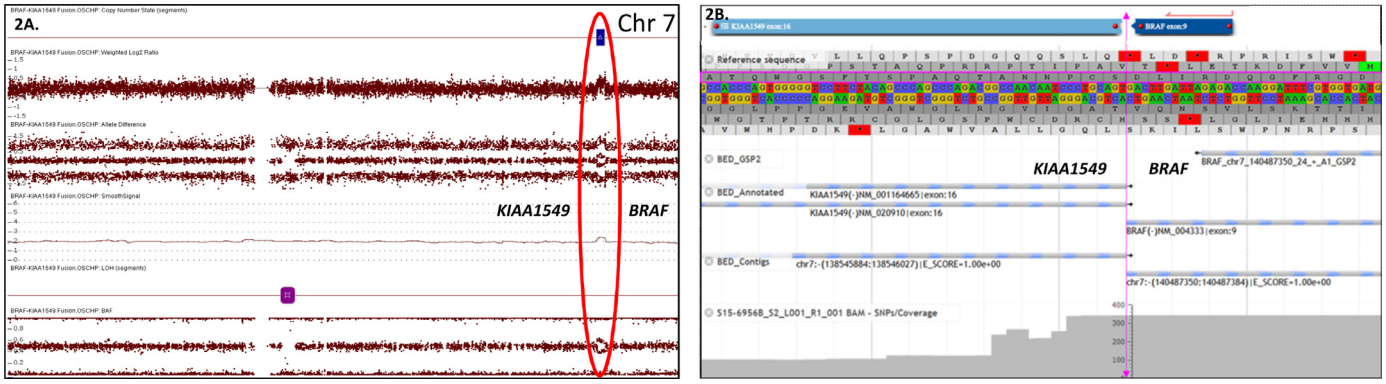

Fig. 2. The most frequent genetic alteration in pilocytic astrocytoma. A. An approximately 2.0 Mb gain at chromosome 7q34, with breakpoints located in *KIAA1549* and *BRAF*, is consistent with a known tandem duplication event; **B.** NGS data illustrate the *KIAA1549-BRAF* fusion between exon 16 of *KIAA1549* and exon 9 of *BRAF*. Sequencing assays can be used to confirm gene fusions and define breakpoints.
Array: Oncoscan MIP array (ThermoFisher)
Fusion: Anchored Multiplex PCR (Archer)

Angiocentric gliomas

These low-grade (WHO Grade I), predominantly cerebral tumors are diagnosed mostly in children and young adults and are often associated with epilepsy [64]. Histologically they are distinguished by bipolar spindled cells that circumscribe blood vessels. Several genomic studies have identified unbalanced rearrangements involving *MYB* (6q23) that can lead to chimeric fusions involving *MYB* with *QKI* or *ESR1* [5,96,127].

Meningiomas

Meningiomas are common primary CNS tumors that typically present as well-demarcated masses arising from the dura mater. They are graded by histologic features, according to WHO criteria, from grades I to III. WHO grade I meningiomas may be referred to as benign meningiomas as they carry lower risks of recurrence and progression compared with that of higher-grade counterparts. Copy number evaluations of these lower grade tumors show two common profiles, including monosomy 22 as a sole aberration or no CNA at all [6,7,62]. Approximately 2% of Grade I meningiomas are classified as angiomatous, which are associated with a distinct genomic profile that features multiple polysomies ([1,6,7]; see Table 2).

Grade II, or atypical meningiomas, are more likely to recur or progress than grade I tumors [82]. The most common CMA findings in atypical meningiomas include 1p deletion – not necessarily whole arm – monosomy 14, 18q deletion, and monosomy 22 (additional aberrations described in Tables). It is not uncommon for some meningiomas to be classified as WHO Grade I, but with focal atypical features, to then show genomic signatures characteristic of Grade II tumors; these outcomes are consistent with the identification of genomic changes that precede histologic changes and may provide support for more frequent follow up of these patients, as these meningiomas may tend towards earlier recurrence and increased likelihood of progression to higher grade. Interestingly, histologically atypical meningiomas with predominant blood vessels can show genomic features of both angiomatous and atypical tumors, i.e., 1p loss, monosomy 14, and multiple polysomies [6,7,55,62].

Finally, Grade III, or anaplastic, meningiomas are extremely aggressive and display high rates of recurrence with markedly reduced patient survival (50% five-year survival rate). By CMA analysis, one recurrent finding in these tumors is *CDKN2A* loss (9p21.3) [6,7] (Fig. 3). While 9p deletions have been described in atypical meningiomas, it is unclear whether some of these tumors may have been more appropriately classified as the anaplastic variety. The classification of specific genomic findings in meningiomas supports the notion that grading based on histologic criteria alone does not fully explain the behavior of some tumors, particularly those classified as WHO grades I and II tumors. Focal gains or amplifications involving 17q have been reported as a recurrent finding in higher grade meningiomas — WHO Grades II or III [17,124]. Finally, while tetraploidy has been observed in meningiomas, the clinical significance of this finding has not been fully elucidated [4]. Whole genome copy number analysis offers an opportunity to provide better clarity as to the potential behavior of these tumors.

Ependymomas

Ependymomas are a group of glial tumors affecting both adults and children that vary widely in terms of aggressiveness, which in turn may correlate more with clinicopathologic and genomic features than with histologic findings. While ependymomas most often arise in the supratentorial region or the posterior fossa, they can also develop in the spinal cord. Regardless of location, reliance on histology alone for prognoses has been imperfect for tumor classification. The addition of cytogenetic and genomic data has improved classification and therefore impacted both diagnosis and prognosis for these tumors [30,58]. While the 2016 WHO classifies ependymomas into three histologic grades, it is interesting that no association between tumor grade and survival has been established, perhaps in part due to the inherent subjectivity in assigning histologic criteria [30,33]. As a result, the assignment of specific ependymoma histology-based tumor grades has been losing favor [64].

Recently, DNA methylation profiling was used to classify ependymomas into three major anatomic groups and nine subgroups ([83]; Fig. 4A–C for examples). Balanced genomes that lack any CNA can be seen in tumors from all three anatomical sites (supratentorial, posterior fossa, or spinal). Specific findings in two subgroups of supratentorial tumors include chromothripsis of 11q that leads to fusion of *RELA* with various partners

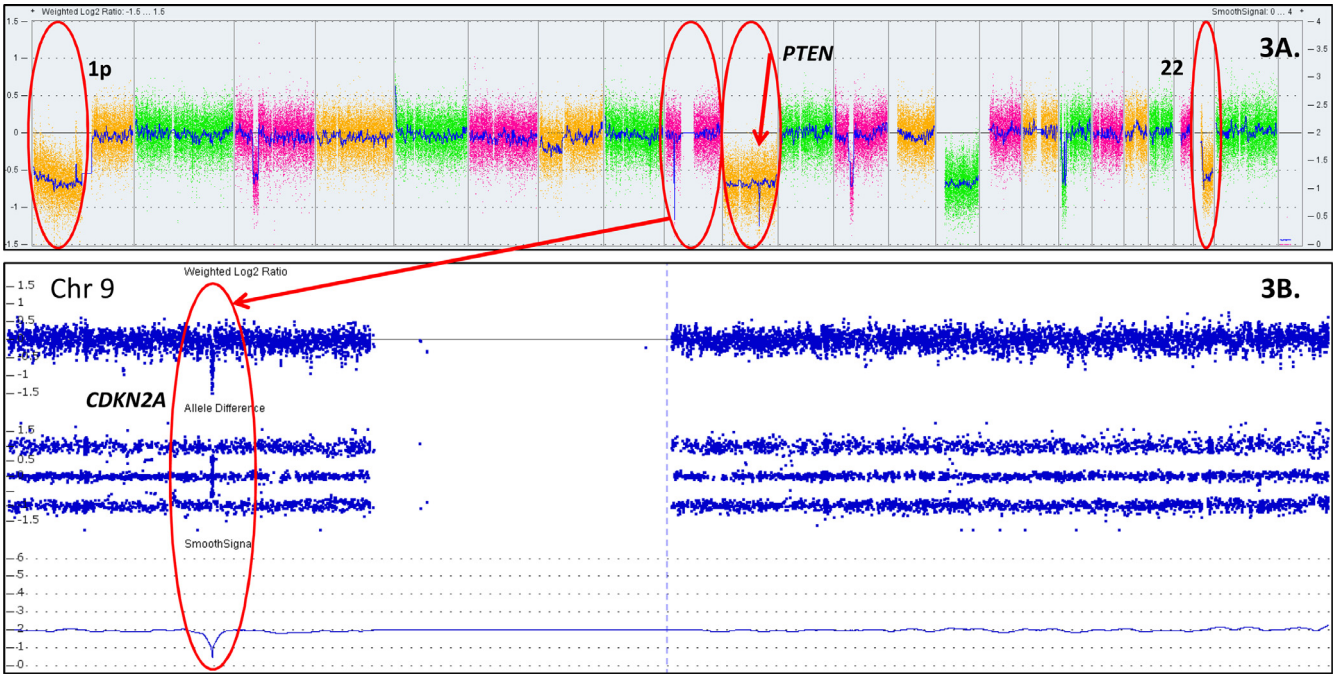

Fig. 3. Anaplastic meningioma showing multiple copy number alterations. Among the aberrations present in this example are losses of 1p, 10, and 22 (A) as well as homozygous loss of *CDKN2A/B* on chromosome 9p (A, B) and homozygous loss of *PTEN* on chromosome 10q (A, with arrow).
Oncoscan MIP array (ThermoFisher)

in aggressive ST-EPN-RELA tumors, and fusions involving *YAP1* (ST-EPN-YAP1) [83,84,87]. Posterior fossa tumors are largely copy number neutral, but tumors in the PF-EPN-B group can be polyploid. Finally, spinal ependymomas can be copy number neutral while carrying *NF2* mutations (SP-EPN subgroup). Some can show polyploidy (SP-MPE subgroup) or a 6q deletion (SP-SE tumors). Other studies have also demonstrated that gain of 1q and focal *CDKN2A* losses can be associated with relatively poor prognostic outcomes [58].

Embryonal tumors

Previously termed primitive neuroectodermal tumors (PNET), embryonal neoplasms comprise a group of tumors seen primarily in the pediatric age group that are histologically characterized by a poorly differentiated or undifferentiated appearance. Embryonal neoplasms are overall aggressive tumors and are designated as WHO grade IV, though some do respond well to treatment. Classically, these tumors were named based upon the location where they arose. Modern genomic investigation has provided even more accurate classification and subclassification [63,64].

Medulloblastomas

Medulloblastomas (MB) are primitive embryonal tumors that typically arise in the cerebellum; they are the most frequent malignant tumor in children [64]. Histologically, all MB are considered WHO Grade IV tumors. The application of CMA analysis to these tumors helps in distinguishing four molecular subgroups (WNT-activated, SHH-activated, Group 3, and Group 4 tumors). The 2016 WHO defines diagnosis of these tumors using a combination of histopathologic and genomic criteria, including copy number, methylation, and transcription-based profiles, and assignment to one of these molecular subgroups is often critical to proper clinical management that may include use of biomarker-based targeted treatments [36,56,77,119].

WNT-activated tumors are primarily observed in children, though rarely in infants, and comprise approximately 10% of MB; 80% are distinguished genetically by monosomy 6 as a sole copy number change ([25]; Shih [56,108]) (Fig. 5A). 90% of WNT-activated MB show mutations in *CTNNB1* [77]. WNT-activated tumors, despite being classified histologically as WHO Grade IV tumors, carry an excellent prognosis [64].

SHH-activated tumors comprise approximately 30% of MB and are divided by the 2016 WHO into those with wildtype or mutant *TP53* [64]. Copy number analysis of the former category can include loss of 9q (*PTCH1*) and 10q (*PTEN, SUFU*) as well as mutations in several genes (see Table 1). *TP53*-mutant SHH-activated tumors can show amplification of *MYCN* or *GLI2*, as well as 17p (*TP53*) loss, and can be associated with chromothripsis [99] (Fig. 5B). A relatively large-scale study shows important differences between pediatric SHH MB, in which 10q loss (*PTEN, SUFU*) and *MYCN* amplification are more frequent, and adult SHH MB, in which polysomy 2, 17p loss (*TP53*), 17q gain, or *GLI2* amplification are associated with poor prognostic outcomes ([76,57])

The presence of an isodicentric (17)(p11.2) (often described in the literature as an isochromosome 17q10) can be observed in either Group 3 or Group 4 tumors, particularly if *MYC* or *MYCN* amplification is also present (Shih [77,108,119]; Northcott PA et al, 2014) (Fig. 5C). Group 3 MB can arise in infancy or childhood and are often distinguished by *MYC* amplification or the isodicentric (17)(p11.2). Note that there are several shared features between Group 3 and Group 4 tumors that can complicate clear genomic distinction between these tumors [77]. A recent publication has delineated a specific copy number profile for these tumors (namely, two or more of either chromosome 7 gain, chromosome 8 loss, or chromosome 11 loss) that may be associated with a better prognosis [40].

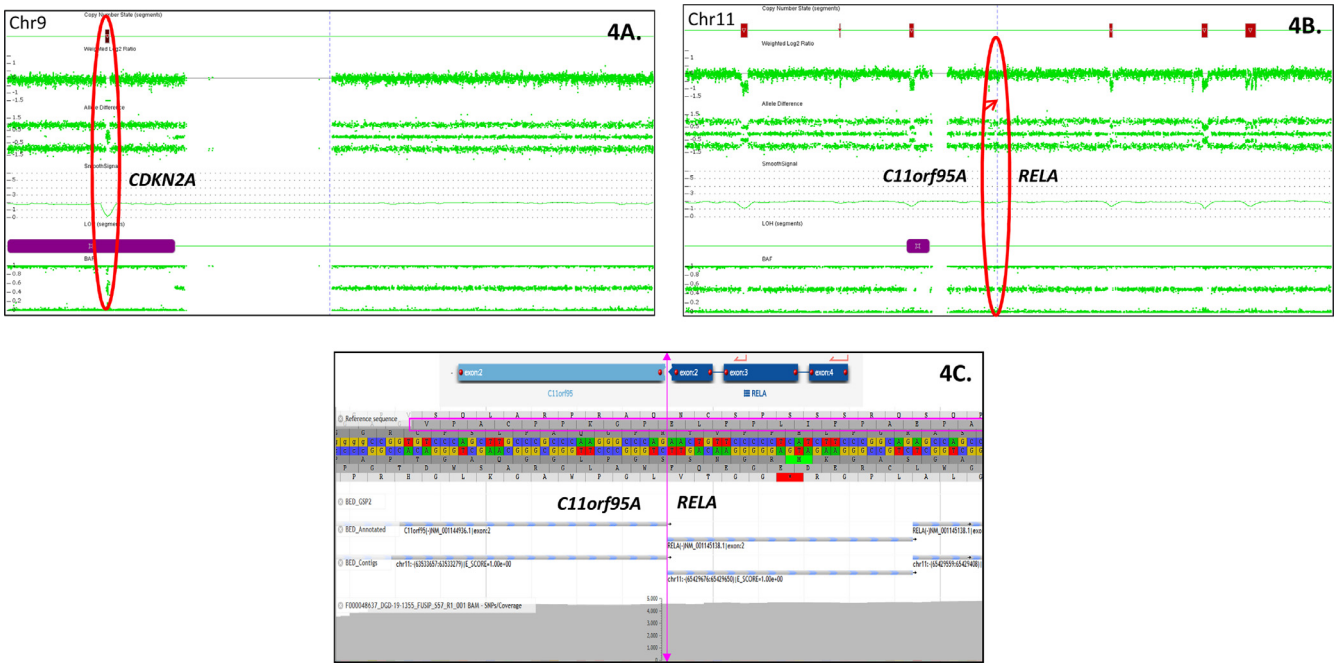

Fig. 4. Some supratentorial ependymomas can be defined by a *RELA* fusion. These tumors may show *CDKN2A/B* deletion on chromosome 9 (**A**) and multiple, possibly complex aberrations on chromosome 11, which may be associated with chromothripsis in some tumors (**B**). Within the context of a supratentorial ependymoma, these changes should prompt evaluation for a *RELA* fusion. (**C**) NGS results demonstrate *C11orf95-RELA* fusion between exon 2 of *C11orf95* and exon 2 of *RELA*.
Array: Oncoscan MIP array (ThermoFisher)
Fusion: Anchored Multiplex PCR (Archer)

Caution should be used in guarding against simplifying this classification scheme, however, as analysis of CNA across the genome sometimes is insufficient to definitively assign a MB to a subgroup [56]. In addition, the availability of mutation data is an invaluable complement to copy number data in the classification of MB subgroups.

Atypical teratoid/rhabdoid tumors (AT/RT)

These tumors often arise in young children, occur rarely in adults, and can appear histologically similar to MBs, among other embryonal neoplasms [64]. The defining genetic abnormality in AT/RT is an alteration or alterations of *SMARCB1* (previously known as *INI1*) (Supplementary Fig. 2). Some of these tumors have *SMARCB1* loss, which is detectable by CMA; 20-24% of tumors showing homozygous *SMARCB1* deletions [9,44]. In some tumors, *SMARCB1* SNV are identified instead and are often accompanied by a heterozygous loss of *SMARCB1* or an entire chromosome 22 [8,9]. *SMARCB1* is a component of the SWI/SNF complex involved in modification of chromatin structure [102]. It is important to note that rare AT/RT tumors lack *SMARCB1* alterations, and instead have *SMARCA4* mutations [107]. More recently, a 2015 analysis [48] identified three epigenetic classes of AT/RT associated with differences in patient demographics, tumor location and specific *SMARCB1* alterations.

Embryonal tumor with multilayered rosettes (ETMR)

These aggressive tumors arise in the cerebrum, cerebellum, or brain stem and can be histologically challenging; in the past, they were classified under a range of different histologic designations. The 2016 WHO recognizes this new category as tumors having a focal amplification/fusion event involving the C19MC locus at 19q13.42 (Supplementary Fig. 3) [64]. Among other CNA that can be present (see Table 1; [21,59,114]), the 19q13.42 amplicon includes a proximal breakpoint involving the chromosome 19 microRNA cluster (*C19MC)* and a distal breakpoint disrupting *TTYH1*. Complex rearrangements at the locus often result in *C19MC-TTYH1* fusion that enables *C19MC* expression via the *TTYH1* promoter [54,59]. The resulting amplification driven fusion can be identified easily by CMA.

Choroid plexus tumors

Choroid plexus papillomas

Choroid plexus papillomas (CPP, WHO grade I) and atypical choroid plexus papillomas (aCPP, WHO grade II) are histologically and genetically similar tumors distinguished primarily by the degree of mitotic activity found on histologic examination, with aCPP displaying more frequent mitoses than CPP. These tumors arise intraventricularly near choroid plexus tissue, and share a morphologic resemblance to non-neoplastic choroid plexus [64]. In terms of copy number aberrations, CPP and aCPP tend to exhibit numerous whole-chromosome gains with few losses (hyperdiploidy) [64,69].

Choroid plexus carcinomas

Like choroid plexus papillomas, choroid plexus carcinomas (CPC) are also epithelial tumors that often arise in the vicinity of choroid plexus tissue (in this case, the lateral ventricles); however, CPC display classic histologic features of malignancy. Genomic analysis of CPC has revealed *TP53* mutations in

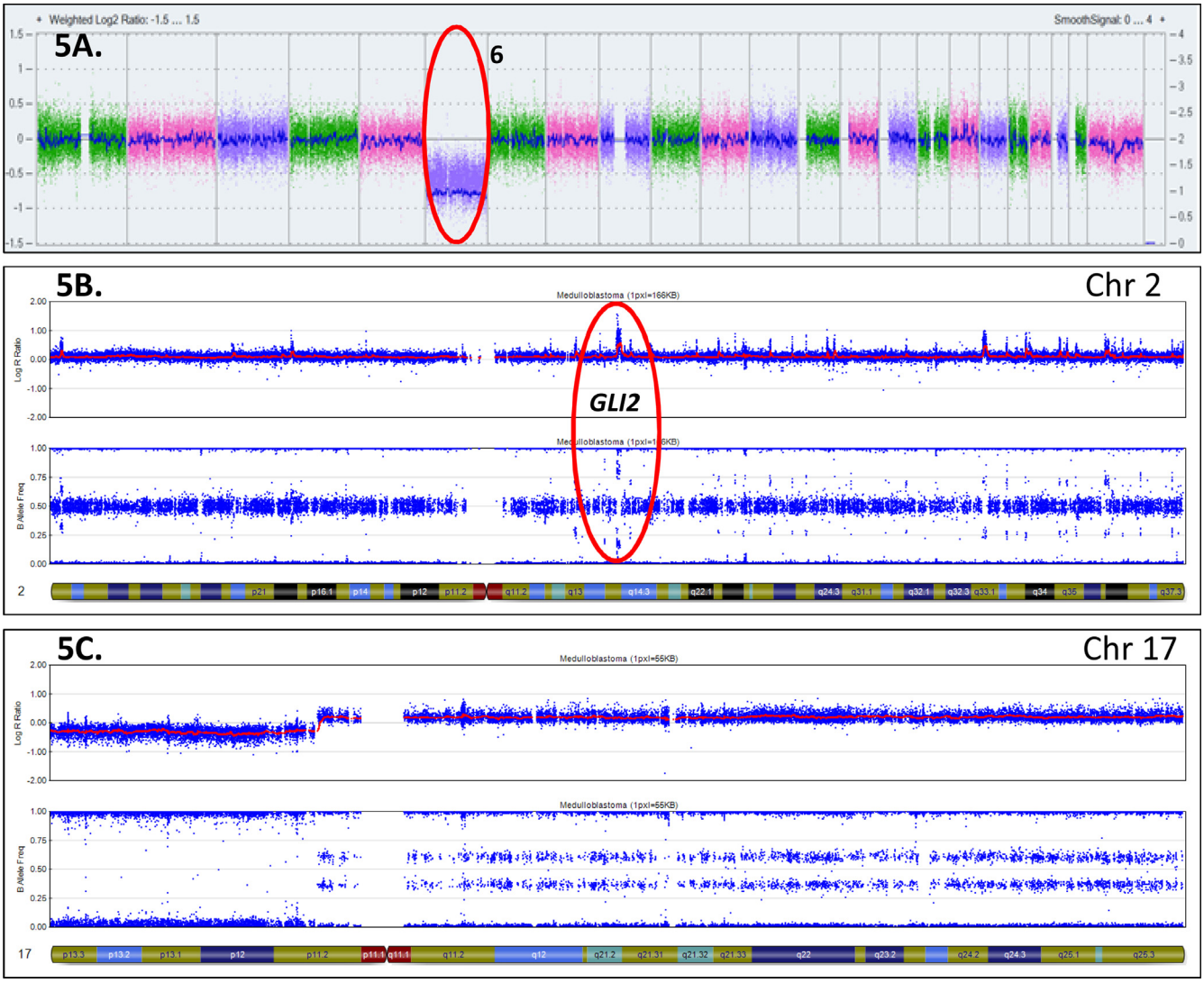

Fig. 5. Characteristic CNAs in medulloblastoma subgroups. A. Monosomy 6 is often a solitary finding in WNT-activated medulloblastomas. **B.** A series of focal gains on chromosome 2, including *GLI2* (2q14.2) amplification associated with SHH-activated tumors. **C.** Partial 17p loss with gain of proximal 17p and the entirety of 17q, consistent with an isodicentric (17)(p11.2) in non-WNT/non-SHH tumors.
Infinium CytoSNP-850K Beadchip (Illumina)

approximately 50% of these tumors. CPC tend to show complex copy number changes, including numerous chromosome-wide gains and losses, also in contrast to the genomic profiles of CPP [64,69]. Methylation profiling has revealed additional additional alterations that may prove useful in further determining risk assessment [120].

Conclusion

Our understanding of the biology and diagnosis of primary CNS tumors has grown exponentially in the last decade, and this is appropriately reflected in the 2016 WHO, which correctly incorporates genomic data into the diagnostic algorithm. DNA copy number data comprises a portion of the genomic information incorporated into the 2016 WHO guidelines as well as other ongoing efforts to improve classification; many of the relevant CNAs can be detected by CMA analysis. Along these lines, CMA is most useful to confirm histologic diagnosis and to facilitate molecular classification of certain primary CNS tumors (e.g., medulloblastoma, oligodendroglioma, pilocytic astrocytoma). CMA can be performed using FFPE tissues as a starting material and has the potential to improve treatment decisions when tumor classification is impacted by identification of CNAs. Many research efforts across large patient cohorts have been helpful in demonstrating molecular heterogeneity across tumors types, which increases the value of clinical implementation of whole genome copy number analyses.

Efforts to develop good, interdisciplinary working relationships between neuropathology and laboratory geneticists have allowed implementation of this clinical testing to proceed in a thoughtful way that optimizes and improves patient care. The application of methylation and transcription-based analyses has contributed to the burgeoning data that can be applied towards understanding the molecular basis of many CNS tumors, but together these approaches have not yet been widely adopted into standard clinical laboratory practice. However, it is not difficult to imagine that the next avenue for clinical genetics laboratories to explore will involve incorporation of methylation and RNA-based assays into existing algorithms for DNA-based CNA and mutation testing. Such a comprehensive integrated approach will capitalize on insights that

have been made into cancer genomics and will ultimately improve diagnostics. As diagnosis forms the foundation of medical care, refinements to classification will only better enable treating physicians in assessing prognosis and providing well-tailored therapies.

Acknowledgments

The authors state that they have no conflicts of interest to disclose. We would like to thank the Board of Directors and membership of the Cancer Genomics Consortium for their assistance in the review and completion of this manuscript.

Supplementary materials

Supplementary material associated with this article can be found, in the online version, at doi:10.1016/j.cancergen.2020.02.004.

References

[1] Abedalthagafi MS, et al. Angiomatous meningiomas have a distinct genetic profile with multiple chromosomal polysomies including polysomy of chromosome 5. Oncotarget 2014;5(21):10596–606 Nov 15PMID: 25347344.
[2] American Cancer Society. Cancer Facts & Figures 2019. Atlanta: American Cancer Society; 2019.
[3] Appin CL, Brat DJ. Biomarker-drive diagnosis of diffuse gliomas. Mole Aspects Med 2015:87–96 Nov; 45PMID: 26004297.
[4] Baia GS, et al. Notch activation is associated with tetraploidy and enhanced chromosomal instability in meningiomas. Neoplasia 2008;10(6):604–12 JunPMID: 18516297.
[5] Bandopadhayay P, et al. MYB-QKI rearrangements in angiocentric glioma drive tumorigenicity through a tripartite mechanism. Nat Genet 2016;48(3):273–82 Feb 24PMID: 26829751.
[6] Bi WL, et al. Meningioma genomics: diagnostic, prognostic, and therapeutic applications. Front Surg 2016;3:40 aJul 6PMID: 27458586.
[7] Bi WL et al., Genomic landscape of intracranial meningiomas J Neurosurg. 2016b. Jan 15:1-11. PMID: 26771848.
[8] Biegel JA, et al. Germline and acquired mutations of INI1 in atypical teratoid and rhabdoid tumors. Cancer Res 1999;59(1):74–9 Jan 1PMID: 9892189.
[9] Biegel JA, et al. Molecular genetics of atypical teratoid/rhabdoid tumors. Neurosurg Focus 2006;20(1):E11 Jan 15PMID: 16459991.
[10] Biernat W, et al. Predominant expression of mutant EGFR (EGFRvIII) is rare in primary glioblastomas. Brain Pathol 2004;14(2):131–6 PMID: 15193025.
[11] Bonfield CM, Steinbok P. Pediatric cerebellar astrocytoma: a review. Child Nerv Syst 2015;31(10):1677–85 PMID: 26351221.
[12] Brat DJ, et al. Comprehensive, integrative genomic analysis of diffuse lower-grade gliomas. N Engl J Med 2015;37(26):2481–98 June 25PMID: 26061751.
[13] Brat DJ, et al. cIMPACT-NOW update 3: recommended diagnostic criteria for "Diffuse astrocytic glioma, IDH-wildtype, with molecular features of glioblastoma, WHO grade IV". Acta Neuropathol 2018;136(5):805–10 NovPMID: 30259105.
[14] Brat DJ, et al. cIMPACT-NOW update 5: recommended grading criteria and terminologies for IDH-mutant astrocytomas. Acta Neuropathol 2020 Jan 29PMID: 31996992.
[15] Brennan CW, et al. The somatic genomic landscape of glioblastoma. Cell 2013;155(2):462–77 PMID: 24120142.
[16] Buczkowicz P, et al. Genomic analysis of diffuse intrinsic pontine gliomas identifies three molecular subgroups and recurrent activating ACVR1 mutations. Nat Genet 2014;46(5):451–6 MayPMID: 24705254.
[17] Büschges R, et al. Allelic gain and amplification on the long arm of chromosome 17 in anaplastic meningiomas. Brain Pathol 2002;12(2):145–53 AprPMID: 11958368.
[18] Capper D, et al. Practical implementation of DNA methylation and copy-number-based CNS tumor diagnostics: the Heidelberg experience. Acta Neuropathol 2018;136(2):181–210 AugPMID: 29967940.
[19] Capper D, et al. DNA methylation-based classification of central nervous system tumours. Nature 2018;555(7697):469–74 Mar 22PMID: 29539639.
[20] CBTRUS statistical report: primary brain and central nervous system tumors diagnosed in the United States in 2008-2012. Ostrom QT, Gittleman H, Fulop J, Liu M, Blanda R, Kromer C, Wolinsky Y, Kruchko C, Barnholtz-Sloan JS. Neuro Oncol 2015 Oct;17 Suppl 4:iv1-iv62. Epub 2015 Oct 27.
[21] Ceccom J, et al. Embryonal tumor with multilayered rosettes: diagnostic tools update and review of the literature. Clin Neuropathol 2014;33(1):15–22 Jan-FebPMID: 23863344.
[22] Chappé C, et al. Dysembryoplastic neuroepithelial tumors share with pleomorphic xanthoastrocytomas and gangliogliomas BRAF(V600E) mutation and expression. Brain Pathol 2013;23(5):574–83 SepPMID: 23442159.
[23] Cimino PJ, et al. Multidimensional scaling of diffuse gliomas: application to the 2016 World Health Organization classification system with prognostically relevant molecular subtype discovery. Acta Neuropathol Commun 2017;5:39 PMID: 28532485.
[24] Cin H, et al. Oncogenic FAM131B-BRAF fusion resulting from 7q34 deletion comprises an alternative mechanism of MAPK pathway activation in pilocytic astrocytoma. Acta Neuropathol 2011(6):763–74 Jun;121PMID: 21424530.
[25] Clifford SC, et al. Wnt/Wingless pathway activation and chromosome 6 loss characterize a distinct molecular subgroup of medulloblastomas associated with a favorable prognosis. Cell Cycle 2006(22):2666–70 Nov;5PMID: 17172831.
[26] Cohen A, et al. DNA copy number analysis of Grade II-III and Grade IV gliomas reveals differences in molecular ontogeny including chromothripsis associated with IDH mutation status. Acta Neuropathol Commun 2015;3:34 Jun 20PMID: 26091668.
[27] Di Stefano AL, et al. Detection, characterization, and inhibition of FGFR-TACC fusions in IGH wildtype glioma. Clin Cancer Res 2015;21(14):3307–17 Jul 15PMID: 25609060.
[28] Eckel-Passow JE, et al. Glioma groups based on 1p/19q, IDH, and TERT promoter mutations in tumors. N Engl J Med 2015;372(26):2499–508 Jun 25PMID: 26061753.
[29] Ellezam B, et al. Recurrent PIK3CA mutations in rosette-forming glioneuronal tumor. Acta Neuropathol 2012;123(2):285–7 FebPMID: 21997360.
[30] Ellison DW, et al. Histopathological grading of pediatric ependymoma: reproducibility and clinical relevance in European trial cohorts. J. Negat. Results Biomed 2011;10:7 PMID: 21627842.
[31] Erdmann J. All aboard: Will molecular tumor boards help cancer patients? Nat Med 2015;21(7):655–6 JulPMID: 26151320. doi:10.1038/nm0715-655.
[32] Faulkner C, et al. BRAF fusion analysis in pilocytic astrocytomas: KIAA1549-BRAF 15-9 fusions are more frequent in the midline than within the cerebellum. J Neuropathol Exp Neurol 2015;74(9):867–72 SepPMID: 26222501.
[33] Figarella-Branger D. Prognostic factors in intracranial ependymomas in children. J Neurosurg 2000;93(4):605–13 OctPMID: 11014538.
[34] Fontebasso AM, et al. Non-random aneuploidy specifies subgroups of pilocytic astrocytoma and correlates with older age. Oncotarget 2015;6(31):31844–56 Oct 13PMID: 26378811.
[35] Furgason JM, et al. Whole genome sequencing of glioblastoma multiforme identifies multiple structural variations involved in EGFR activation. Mutagenesis 2014;29(5):341–50 SepPMID: 25103728.
[36] Gajjar A, et al. Molecular insights into pediatric brain tumors have the potential to transform therapy. Clin Cancer Res 2014;20:5630–40 PMID: 25398846.
[37] Gan HK, et al. The EGFRvIII variant in glioblastoma multiforme. J Clin Neurosci 2009;16(6):748–54 PMID: 19324552.
[38] Gessi M, et al. FGFR1 mutations in Rosette-forming glioneuronal tumors of the fourth ventricle. J Neuropathol Exp Neurol 2014;73(6):580–4 JunPMID: 24806303.
[39] Giunti L, et al. Genome-wide copy number analysis in pediatric glioblastoma multiforme. Am J Cancer Res 2014;4(3):293–303 May 26PMID: 24959384.
[40] Goschzik T, et al. Prognostic effect of whole chromosomal aberration signatures in standard-risk, non-WNT/non-SHH medulloblastoma: a retrospective, molecular analysis of the HIT-SIOP PNET 4 trial. Lancet Oncol 2018;19(12):1602–16 DecPMID: 30392813.
[41] Griffin CA, et al. Identification of der(1;19)(q10;p10) in five oligodendrogliomas suggests mechanism of concurrent 1p and 19q loss. J Neuropathol Exp Neurol 2006;65(10):988–94 PMID: 17021403.
[42] Gupta M, Young BD. Application of SNP genotype arrays to determine somatic changes in cancer. Methods Mol Biol 2009;538:179–206 PMID: 19277572.
[43] Hasenahuer MA, et al. Pockets as structural descriptors of EGFR kinase conformations. PLoS One 2017;12(12) Dec 11PMID: 29228029.
[44] Hasselblatt M, et al. High-resolution genomic analysis suggests the absence of recurrent genomic alterations other than SMARCB1 aberrations in atypical teratoid/rhabdoid tumors. Genes Chrom Cancer 2013;52:185–90 PMID:23074045.
[45] Horbinski C. Something old and something new about molecular diagnostics in gliomas. Surg Pathol Clin 2012;5(4):919–39 Dec 1PMID: 23459421.
[46] Jaunmuktane Z, et al. Methylation array profiling of adult brain tumours: diagnostic outcomes in a large, single centre. Acta Neuropathol Commun 2019;7(1):24 Feb 20PMID: 30786920.
[47] Jenkins RB, et al. A t(1;19)(q10;p10) mediates the combined deletions of 1p and 19q and predicts a better prognosis of patients with oligodendroglioma. Cancer Res 2006;66(20):9852–61 Oct 15PMID: 17047046.
[48] Johann PD, et al. Atypical teratoid/rhabdoid tumors are comprised of three epigenetic subgroups with distinct enhancer landscapes. Cancer Cell 2016;29(3):379–93 2016 Mar 14PMID: 26923874.
[49] Jones DT, et al. Genomic analysis of pilocytic astrocytomas at 0.97 Mb resolution shows an increasing tendency towards chromosomal copy number change with age. J Neuropathol Exp Neurol 2006;65(11):1049–58 NovPMID: 17086101.
[51] Jones DT, et al. Tandem duplication producing a novel oncogenic BRAF fusion gene defines the majority of pilocytic astrocytomas. Cancer Res 2008;68(21):8673–7 Nov 1PMID: 18974108.
[52] Jung H-S, et al. Utilization of the Oncoscan microarray assay in cancer diagnostics. Applied Cancer Res 2017;37:1.
[53] Killela PJ, et al. The genetic landscape of anaplastic astrocytoma. Oncotarget 2014;5(6):1452–7 PMID: 24140581.
[54] Kleinman CL, et al. Fusion of TTYH1 with the C19MC microRNA cluster drives expression of a brain-specific DNMT3B isoform in the embryonal brain tumor ETMR. Nat Genet 2014;46(1):38–44 JanPMID: 24316981.

[55] Krayenbuhl N, et al. De novo versus transformed atypical and anaplastic meningiomas: comparisons of clinical course, cytogenetics, cytokinetics, and outcome. Neurosurgery 2007;61(3):495–503 SepPMID: 17881961.
[56] Kool M, et al. Molecular subgroups of medulloblastoma: an international meta-analysis of transcriptome, genetic aberrations, and clinical data of WNT, SHH, Group 3 and Group 4 medulloblastomas. Acta Neuropathol 2012;123(4):473–84 AprPMID: 22358457.
[57] Kool M, et al. Genome sequencing of SHH medulloblastoma predicts genotype-related response to smoothened inhibition. Cancer Cell 2014;25(3):393–405 Mar 17PMID: 24651015.
[58] Korshunov A, et al. Molecular staging of intracranial ependymoma in children and adults. J Clin Oncol 2010;28(19):3182–90 Jul 1PMID: 20516456.
[59] Korshunov A, et al. Embryonal tumor with abundant neuropil and true rosettes (ETANTR), ependymoblastoma, and medulloepithelioma share molecular similarity and comprise a single clinicopathological entity. Acta Neuropathol 2014;128(2):279–89 AugPMID: 24337497.
[60] Lasorella A, et al. FGFR-TACC gene fusions in human glioma. Neuro Oncol 2017;19(4):475–83 Apr 1PMID: 27852792.
[61] Lee D, et al. BRAF V600E mutations are frequent in dysembryoplastic neuroepithelial tumors and subependymal giant cell astrocytomas. J Surg Oncol 2015;111(3):359–64 MarPMID: 25346165.
[62] Lee Y, et al. Genomic landscape of meningiomas. Brain Pathol 2010;20(4):751–62 JulPMID: 20015288.
[63] Louis DN, Ohgaki H, Wiestler OD, Cavenee WK, Burger PC, Jouvet A, Scheithauer BW, Kleihues P. The 2007 WHO classification of tumours of the central nervous system. Acta Neuropathol 2007;114(2):97–109 AugPMID: 17618441.
[64] Louis DN, Perry A, Reifenberger G, von Deimling A, Figarella-Branger D, Cavenee WK, Ohgaki H, Wiestler OD, Kleihues P, Ellison DW. The 2016 World Health Organization classification of tumors of the central nervous system: a summary. Acta Neuropathol 2016;131:803–20 PMID: 27157931.
[65] Louis DN, Giannini C, Capper D, et al. cIMPACT-NOW update 2: diagnostic clarifications for diffuse midline glioma, H3 K27M-mutant and diffuse astrocytoma/anaplastic astrocytoma, IDH-mutant. Acta Neuropathol 2018;135:639 PMID: 29497819.
[66] Louis DN, et al. Data sets for the reporting of tumors of the central nervous system. Arch Pathol Lab Med 2019 Jun 20. PMID: 31219344.
[67] Lu VM, et al. Impact of the H3K27M mutation on survival in pediatric high--grade glioma: a systematic review and meta-analysis. J Neurosurg Pediatr 2018:1–9 Nov 1PMID: 30544362.
[68] Malhotra A, et al. Breakpoint profiling of 64 cancer genomes reveals numerous complex rearrangements spawned by homology-independent mechanisms. Genome Res 2013;23(5):762–76 MayPMID: 23410887.
[69] Merino DM, et al. Molecular characterization of choroid plexus tumors reveals novel clinically relevant subgroups. Clin Cancer Res 2015;21(1):184–92 Jan 1PMID: 25336695.
[70] McNulty SN, Cottrell CE, Vigh-conrad KA, Carter JH, Heusel JW, Ansstas G, Dahiya S. Beyond sequence variation: assessment of copy number variation in adult glioblastoma through targeted tumor somatic profiling. Hum Pathol 2018 aDec. 27. Epub ahead of print. PMID: 30594748.
[71] McNulty SN, Schwetye K, Goldstein M, Carter J, Schmidt RE, Ansstas G, Tsien CI, Kim AH, Dahiya S. Analysis of point mutations and copy number variation in Grade II and III meningioma. Exp Mol Pathol 2018;105(3):328–33 bDecPMID: 30316860.
[72] Mikhail FM, et al. Technical laboratory standards for interpretation and reporting of acquired copy-number abnormalities and copy-neutral loss of heterozygosity in neoplastic disorders: a joint consensus recommendation from the American College of Medical Genetics and Genomics (ACMG) and the Cancer Genomics Consortium (CGC). Genet Med 2019;21(9):1903–15 SepPMID: 31138931.
[73] Mirchia K, et al. Total copy number variation as a prognostic factor in adult astrocytoma subtypes. Acta Neuropathol Commun 2019;7:8 PMID: 31177992.
[74] Molenaar RJ et al., Wild-type and mutated IDH1/2 enzymes and therapy responses. 2018. Oncogene Apr;37(15):1949-1960 and Erratum in: Oncogene 2018 Oct. 37(43):5810. PMID: 29367755.
[75] National Comprehensive Cancer Network. Central Nervous System Cancers (Version 1.2019). https://www.nccn.org/professionals/physician_gls/default.aspx#site.
[76] Northcott PA, et al. Pediatric and adult sonic hedgehog medulloblastomas are clinically and molecularly distinct. Acta Neuropathol 2011;122(2):231–40 AugPMID: 21681522.
[77] Northcott PA, et al. Subgroup-specific structural variation across 1,000 medulloblastoma genomes. Nature 2012;488(7409) Aug 2PMID: 22832581.
[78] Ohgaki H, et al. Genetic pathways to glioblastoma: a population-based study. Cancer Res 2004;64(19):6892–9 PMID: 15466178.
[79] Ohgaki H, et al. Genetic pathways to primary and secondary glioblastoma. Am J Pathol 2007;170(5):1445–53 MayPMID: 17456751.
[80] O'Keefe C, McDevitt MA, Maciejewski JP. Copy neutral loss of heterozygosity: a novel chromosomal lesion in myeloid malignancies. Blood 2010;115(14):2731–9 Apr 8PMID: 20107230.
[81] Ostrom QT, de Blank PM, Kruchko C, Peterson CM, Liao P, Finlay JL, Stearns DS, Wolff JE, Wolinsky Y, Letterio JJ, Barnholtz-Sloan JS. CBTRUS Statistical Report: Alex's Lemonade Stand Foundation Infant and Childhood Primary Brain and Central Nervous System Tumor Diagnosed in the United States in 2007-2011. Neuro-Oncol 2015;16(Suppl 10):x1–x36 JanDoi: 10. 1093/neuonc/nou 327.
[82] Ozaki S, et al. Comparative genomic hybridization analysis of genetic alterations associated with malignant progression of meningioma. J Neurooncol 1999;41(2):167–74 JanPMID: 10222437.
[83] Pajtler KW, et al. Molecular classification of ependymal tumors across all CNS compartments, histopathological and age groups. Cancer Cell 2015;27(5):728–43 May 11PMID: 25965575.
[84] Pajtler KW, et al. The current consensus on the clinical management of intracranial ependymoma and its distinct molecular variants. Acta Neuropathol 2017;133:5–12 JanPMID: 27858204.
[85] Park AK, et al. Constitutive asymmetric dimerization drives oncogenic activation of epidermal growth factor carboxyl-terminal deletion mutants. Oncotarget 2015;6(11):8839–50 Apr 20PMID: 25826094.
[86] Park PJ. Experimental design and data analysis for array comparative genomic hybridization. Cancer Invest 2008;26(9):923–8 NovPMID: 19034774.
[87] Parker M, et al. c11orf95-RELA fusions drive oncogenic NF-kB signalling in ependymoma. Nature 2014;506(7489):451–5 Feb27and Erratum in Nature 2014, 508(7497):554. PMID: 24553141.
[88] Paugh BS, et al. Integrated molecular genetic profiling of pediatric high–grade gliomas reveals key differences with the adult disease. J Clin Oncol 2010;28(18):3061–8 Jun 20Epub 2010 May 17. PMID: 20479398.
[89] Pekmezci M, et al. The genetic landscape of ganglioglioma. Acta Neuropathol Commun 2018;6(1):47 Jun 7PMID: 29880043.
[90] Phillips JJ, et al. The genetic landscape of anaplastic pleomorphic xanthoastrocytoma. Brain Pathol 2019;29(1):85–96 JanPMID: 30051528.
[91] Pisapia DJ. The updated World Health Organization glioma classification: cellular and molecular origins of adult infiltrating gliomas. Arch Pathol Lab Med 2017;141(12):1633–45 DecPMID: 29189064.
[92] Prabowo AS, et al. Landscape of chromosomal copy number aberrations in gangliogliomas and dysembryoplastic neuroepithelial tumours. Neuropathol Appl Neurobiol 2015;41(6):743–55 OctPMID: 25764012.
[93] Puget S, et al. Mesenchymal transition and PDGFRA amplification/mutation are key distinct oncogenic events in pediatric diffuse intrinsic pontine gliomas. PLoS One 2012;7(2):e30313 PMID: 22389665.
[94] Qaddoumi I, et al. Genetic alterations in uncommon low-grade neuroepithelial tumors: BRAF, FGFR1, and MYB mutations occur at high frequency and align with morphology. Acta Neuropathol 2016;131(6):833–45 JunPMID: 26810070.
[95] Ramkissoon LA, et al. Genomic analysis of diffuse pediatric low-grade gliomas identifies recurent oncogenic truncating rearrangements in the transcription factor MYBL1. PNAS USA 2013;110(20):8188–93 May 14PMID: 23633565.
[96] Ramkissoon SH, et al. Genomic analysis of diffuse pediatric low-grade gliomas identifies recurrent oncogenic rearrangements in the transcription factor MYBL1. PNAS USA 2013;110(20):8188–93 May 14PMID: 23633565.
[97] Ramkissoon SH, et al. Clinical implementation of integrated whole-genome copy number and mutation profiling for glioblastoma. Neuro Oncol 2015;17(10):1344–55 OctPMID: 25754088.
[98] Ramkissoon SH, et al. Clinical targeted exome-based sequencing in combination with genome-wide copy number profiling: precision medicine analysis of 203 pediatric brain tumors. Neuro Oncol 2017;19(7):986–96 July 1PMID:28104717.
[99] Rausch T, et al. Genome sequencing of pediatric medulloblastoma links catastrophic DNA rearrangements with TP53 mutations. Cell 2012;148(1-2):59–71 Jan 20PMID: 22265402.
[100] Reis GF, et al. CDKN2A Loss is associated with shortened overall survival in lower grade (World Health Organization II-III) astrocytomas. J Neuropathol Exp Neurol 2015;74(5):442–52 MayPMID: 25853694.
[101] Reuss DE, et al. ATRX and IDH1-R132H immunohistochemistry with subsequent copy number analysis and IDH sequencing as a basis for an "integrated" diagnostic approach for adult astrocytoma, oligodendroglioma and glioblastoma. Acta Neuropathol 2015;129(1):133–46 JanPMID: 25427834.
[102] Roberts CW, et al. The SWI/SNF complex-chromatin and cancer. Nat Rev Cancer 2004;4(2):133–42 FebPMID: 14964309.
[103] Rodriguez FJ, et al. BRAF duplications and MAPK pathway activation are frequent in gliomas of the optic nerve proper. J Neuropathol Exp Neurol 2012;71(9):789–94 SepPMID: 22892521.
[104] Roth JJ, et al. Diagnostic application of high resolution single nucleotide polymorphism array analysis for children with brain tumors. Cancer Genet 2014;207:111–23 PMID: 24767714.
[105] Roth JJ, et al. Chromosome band 7q34 deletions resulting in KIAA1549-BRAF and FAM131B-BRAF fusions in pediatric low-grade gliomas. Brain Pathol (Zurich, Switzerland) 2015;25:182–92 PMID: 25040262.
[106] Schindler G, et al. Analysis of BRAF V600E mutation in 1,320 nervous system tumors reveals high mutation frequencies in pleomorphic xanthoastrocytoma, ganglioglioma and extra-cerebellar pilocytic astrocytoma. Acta Neuropathol 2011;121(3):397–405 MarPMID: 21274720.
[107] Schneppenheim R, et al. Germline nonsense mutation and somatic inactivation of SMARCA4/BRG1 in a family with rhabdoid tumor predisposition syndrome. Am J Hum Genet 2010;86(2):279–84 Feb12PMID: 20137775.
[108] Shih DJ, et al. Cytogenetic prognostication within medulloblastoma subgroups. J Clin Oncol 2014;32(9):886–96 Mar 20PMID: 24493713.
[109] Shirahata M, et al. Novel improved grading system(s) for IDH-mutant astrocytic gliomas. Acta Neuropathol 2018;136(1):153–66 JulPMID: 29687258.

[110] Sievert AJ, et al. Duplication of 7q34 in pediatric low-grade astrocytomas detected by high-density single-nucleotide polymorphism-based genotype arrays results in novel BRAF fusion gene. Brain Pathol 2009;19(3):449–58 JulPMID: 19016743.
[111] Sim J, et al. Comparison of 1p and 19q status of glioblastoma by whole exome sequencing, array-comparative genomic hybridization, and fluorescence in situ hybridization. Med Oncol 2018;35(5):60 Mar 29PMID: 29600313.
[112] Singh D, et al. Transforming fusions of FGFR and TACC genes in human glioblastoma. Science 2012;337(6099):1231–5 Sept 7PMID: 22837387.
[113] Smith JS, et al. Localization of common deletion regions on 1p and 19q in human gliomas and their association with histological subtype. Oncogene 1999;18(28):4144–52 Jul 15PMID: 10435596.
[114] Spence T, et al. CNS-PNETs with C19MC amplification and/or LIN28 expression comprise a distinct histogenetic diagnostic and therapeutic entity. Acta Neuropathol 2014;128(2):291–303 AugPMID: 24839957.
[115] Stephens, et al. Massive genomic rearrangement acquired in a single catastrophic event during cancer development. Cell 2011;144(1):27–40 Jan 7PMID: 21215367.
[116] Surrey LF, Luo M, Chang F, Li MM. The genomic era of clinical oncology: integrated genomic analysis for precision cancer care. Cytogenet Genome Res 2016;150(3-4):162–75 Dec 22PMID: 28002823.
[117] Suzuki H, et al. Mutational landscape and clonal architecture in grade II and grade III gliomas. Nat Genet 2015;47(5):458–68 MayPMID: 25848751.
[118] Taylor KR, et al. Recurrent activating ACVR1 mutations in diffuse intrinsic pontine glioma. Nat Genet 2014;46(5):457–61 MayPMID: 24705252.
[119] Taylor MD, et al. Molecular subgroups of medulloblastoma: the current consensus. Acta Neuropathol 2012;123:465–72 PMID: 22134537.
[120] Thomas C, et al. Methylation profiling of choroid plexus tumors reveals 3 clinically distinct subgroups. Neuro Oncol 2016;18(6):790–796 JunPMID: 26826203.
[121] Vaubel RA, et al. Recurrent copy number alterations in low-grade and anaplastic pleomorphic xanthoastrocytoma with and without BRAF V600E mutation. Brain Pathol 2018;28(2):172–82 MarPMID: 28181325.
[122] van der Velden DL, et al. Molecular Tumor Boards: current practice and future needs. Ann Oncol 2017;28(12):3070–5 Dec 1PMID: 29045504.
[123] Vennetti S, Huse JT. The evolving molecular genetics of low-grade glioma. Adv Anat Pathol 2015;22(2):94–101 MarPMID:25664944.
[124] Weber RG, et al. Analysis of genomic alterations in benign, atypical, and anaplastic meningiomas: toward a genetic model of meningioma progression. PNAS USA 1997;94(26):14719–24 Dec 23PMID: 9405679.
[125] Wu G, et al. The genomic landscape of diffuse landscape of diffuse intrinsic pontine glioma and pediatric non-brainstem high-grade glioma. Nat Genet 2014;46(5):444–50 MayPMID: 24705251.
[126] Zack TI, et al. Pan-cancer patterns of somatic copy number alteration. Nat Genet 2013;45(10):1134–40 OctPMID: 24071852.
[127] Zhang J, et al. Whole-genome sequencing identifies genetic alterations in pediatric low-grade gliomas. Nat Genet 2013;45(6):602–12 JunPMID: 23583981.
[128] Zheng Z, et al. Anchored multiplex PCR for targeted next-generation sequencing. Nat Med 2014;20(12):147–84 DecPMID: 25384085.
[129] Zhenyi A, et al. Epidermal growth factor receptor (EGFR) and EGFRvIII in glioblastoma (GBM): signaling pathways and targeted therapies. Oncogene 2018;37(12):1561–75 MarPMID: 29321659.